

# Longitudinal Soft Tissue Changes During Periodontal Ligament–Mediated Immediate Implant Placement with the Root-Membrane Technique

Miltiadis M. Mitsias, DDS, MS, PhD<sup>1</sup>/Manuel Bratos, DDS, MS<sup>2</sup>/Konstantinos Siormpas, DDS<sup>3</sup>/  
Michael A. Pikos, DDS<sup>4</sup>/Root Membrane Group<sup>5</sup>/Georgios A. Kotsakis, DDS, MS<sup>6</sup>

**Purpose:** To assess longitudinal volumetric changes during immediate implant placement with simultaneous intentional retention of the buccal aspect of the root. **Materials and Methods:** This study assessed 10 cases drawn from a previously reported cohort that had study casts available pretreatment and at least 2 years after periodontal ligament (PDL)–mediated immediate implant placement. Gypsum casts were scanned using a laser scanner and converted into digital three-dimensional rendered files. The digital casts were superimposed, and semi-automated subtractive assessment was performed via specialized software. **Results:** Data from 10 patients with a minimum of 3 years follow-up (median follow-up time: 42 months) were analyzed. Each person contributed one implant site in this study. All implants successfully maintained osseointegration during the follow-up period and demonstrated optimal soft tissue stability. Changes during the observation period ranged from 0.19 mm (95% confidence interval [95% CI]: 0.10 to 0.28) in the midfacial region 6 mm apical to the mucosal zenith to –0.06 mm (95% CI: –0.14 to 0.02) at 5 mm apical to the base of the distal papilla. All changes were noninferior to pre-extraction baseline measurements based on a 0.5-mm noninferiority margin. **Conclusion:** The intentional retention of the buccal aspect of the root with its periodontal apparatus during immediate implant placement led to optimal soft tissue dimensional stability in the esthetic zone. This technique holds promise for clinical application, and further controlled clinical studies are warranted to determine the comparative clinical benefit from the use of this procedure. INT J ORAL MAXILLOFAC IMPLANTS 2020;35:379–385. doi: 10.11607/jomi.7245

**Keywords:** flapless procedure, immediate placement, PDL-mediated implant placement, surgical procedure

In recent years, the intentional retention of a section of the root has been proposed as a biologic approach to alveolar ridge preservation.<sup>1–3</sup> In contrast to the use

of biomaterials to limit postextraction alveolar ridge dimensional alterations in conventional ridge preservation procedures,<sup>4</sup> the retention of a portion of the root facilitates ridge preservation via the retention of part of the periodontal ligament (ie, PDL-mediated ridge preservation).<sup>1,2</sup> It has long been established that maintenance of the PDL and the vasculature that is part of it or channels through it to reach the alveolar bone is adequate to nourish the alveolar bone and maintain its dimensional stability following loss of the tooth crown.<sup>5</sup> This knowledge has been exploited for pontic site stability in the case of intentional root submergence, but has been impractical for implant sites.<sup>4</sup> That was until the proof-of-concept study by Hürzeler et al<sup>1</sup> that introduced an innovative technique, ie, socket-shield, for combining intentional root submergence with implant placement. This seminal publication demonstrated the feasibility of this technique in an animal model and provided histologic data showing that maintenance of the PDL is achieved when a buccal veneer of the root remains in

<sup>1</sup>Private Practice, Athens, Greece; Department of Periodontology and Implant Dentistry, College of Dentistry, New York University, New York, New York, USA.

<sup>2</sup>Department of Restorative Dentistry, University of Washington, Seattle, Washington, USA.

<sup>3</sup>Private Practice, Larisa, Greece.

<sup>4</sup>Private Practice, Trinity, Florida, USA; Founder, CEO, Pikos Institute.

<sup>5</sup>Department of Periodontics, UTHSCA, San Antonio, Texas, USA.

<sup>6</sup>Department of Periodontics, University of Texas Health at San Antonio, San Antonio, Texas, USA.

**Correspondence to:** Dr Georgios A. Kotsakis, Department of Periodontics, University of Texas Health at San Antonio, 7703 Floyd Curl Drive, San Antonio, TX 78229, USA. Email: Kotsakis@uthscsa.edu

Submitted June 20, 2018; accepted November 25, 2019.

©2020 by Quintessence Publishing Co Inc.

**Table 1 Inclusion and Exclusion Criteria**

Inclusion criteria	Exclusion criteria
Adult patients with noncontributory medical history presented with single hopeless tooth in maxillary anterior dentition	Patients who did not have intact pretreatment and posttreatment full-arch casts
Patients who requested a least-invasive treatment alternative and required no bone grafting	Patients with medical history that contraindicated oral surgical treatment
	Chronic therapy with nonsteroidal anti-inflammatory drugs (NSAIDs), bisphosphonates, and/or corticosteroids
	Patients with sites of moderate or severe periodontal disease

situ postextraction.<sup>1</sup> In fact, the first report providing proof of true integration of implants placed in relation to intentionally retained root fragments in humans was recently published.<sup>6</sup>

Only two longitudinal studies are currently available to provide information on the efficacy of this technique in humans.<sup>2,7</sup> The first longitudinal data from the application of this technique in humans were published by Siormpas et al,<sup>2</sup> and showed that the medium-term success of PDL-mediated implant placement was comparable to that of conventionally placed implants and also documented the absence of remarkable adverse events, which is key to its application in routine clinical practice. The second and most recent longitudinal human data were published by Bäumer et al<sup>7</sup> and reported that the average recession around implants placed in proximity to the retained root sections was less than 0.5 mm over 5 years of follow-up, which was similar to what was noted around adjacent teeth. Nonetheless, the clinical implementation of such novel techniques must be grounded upon robust longitudinal data that report outcomes that can be perceived by patients. As previously suggested, “the principal outcome that ought to be evaluated in future studies is the maintenance of the gingival zenith as a result of the partial maintenance of the periodontal apparatus that leads to stability of the crestolabial tissues.”<sup>2</sup> A challenge with the longitudinal assessment of esthetic outcomes lies in measurement error, which is inherent to the measurement of soft tissue changes over time.

Control for measurement error in the assessment of longitudinal data is more important than in cross-sectional analyses due to the added variability from the comparative assessment methodology. The development of a semi-automated workflow for superimposition of data from dental impressions has, however, vastly increased the precision of subtractive measurements in dental research. Thus, the aim of the present study was to assess longitudinal volumetric changes during PDL-mediated implant placement using digital image superimposition.

## MATERIALS AND METHODS

This retrospective cohort study utilized the same sample population previously reported<sup>2</sup> to assess the longitudinal changes in soft tissue levels following PDL-mediated implant placement. As previously described, all cases included in this cohort were treated for single edentulism in the anterior maxilla. Only participants with a minimum of 3 years of follow-up were enrolled as per the exclusion criteria of the study: participants were excluded if they were chronic users of nonsteroidal anti-inflammatory drugs (NSAIDs), bisphosphonates, and/or corticosteroids; were pregnant; or presented with acute inflammation. Also, sites with moderate or severe periodontal disease and/or sites exhibiting facial clinical attachment loss greater than 3 mm were excluded (Table 1).

### Surgical Procedure

The surgical procedure has been detailed previously, and the steps of the technique along with illustrations have been published elsewhere.<sup>3</sup> In brief, the key steps of the technique utilized in the treatment of the included cases are as follows:

- Removal of the crown of the tooth and reduction of the remaining tooth structure to 1 mm above the bony crest. This is a critical step of the technique, as it allows for the attachment of dentogingival fibers on the retained tooth structure and further supports the stability of gingival levels.
- Initiation of the implant bed preparation through the root canal area of the tooth. This approach was primarily employed to enable the use of the existing tooth structure to restoratively guide implant placement. Importantly, when the existing tooth is malpositioned, careful preparation of the implant osteotomy in the desired position is needed. This step is different than the drilling sequence used in other modifications of PDL-mediated implant placement, as in the authors' opinion, drilling through the body of the root minimizes the risk of dislodging the

buccal root fragment, as opposed to performing a partial extraction prior to preparation. Subsequently specialized diamond burs were utilized to separate the desired buccal root portion from the remaining root and retain it. Root preparation in all cases was performed with a prototype kit (Root Membrane Kit, MegaGen). The remaining root fragments from the lingual and proximal aspects were then removed.

- Placement of a tapered implant was performed in proximity but never in contact with the retained root fragment. Thickness of 0.5 to 1 mm was invariably allowed between the placed implant and the retained root fragment to ascertain the integrity of the latter. This step is very important, as the root fragment is only retained via the PDL following extraction, and torque applied during implant placement has the potential to damage the PDL. It is now well established that this jumping distance between the root section and the implant will fill with mineralized tissue as long as the PDL remains vital.<sup>7,8</sup>
- All implants were immediately loaded with a cement-retained acrylic interim restoration fabricated with no occlusal contacts.

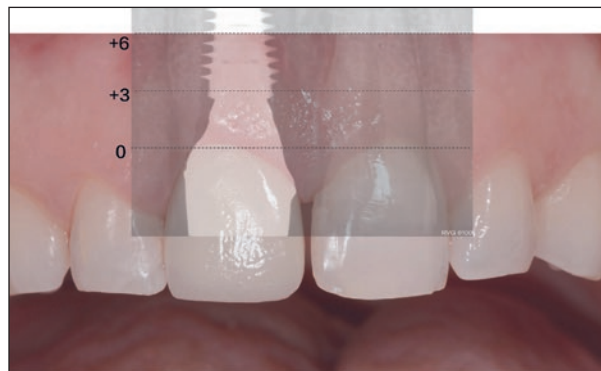
Detailed steps of the surgical technique are described elsewhere.<sup>3</sup> In the present study, 10 cases drawn from the previously reported cohort that had study casts available pretreatment and at least 3 years after PDL-mediated immediate implant placement were assessed.

### Subtractive Assessment

In order to perform longitudinal tissue analyses, gypsum casts were scanned and converted into digital three-dimensional (3D) rendered files. The study casts obtained from the baseline (T0) and the follow-up (T1) impressions were digitalized using a 3D laser scanner (3Shape D2000). Data from the scans were stored in encrypted standard tessellation language (STL) files and extended markup language (XML) files. The analysis was carried out with superimposition software Geomagic Control X.

All baseline STL files (T0) were imported and aligned to the World using the origin of the x-axis and a reference plane that went through the facial cemento-enamel junction (CEJ) of each tooth analyzed. A master grid of three vertical planes perpendicular to the occlusal plane was created. Vertically, three vertical planes were located at mesial, midfacial, and distal papillae covering all the mesiodistal aspects.

The mesh grid was embedded into the digital file and transferred to contact the surface of the STL file. From each of the three projections, three points were selected from the tip of the papillae to the more apical



**Fig 1** Illustration depicting the three planes that were utilized for subtractive measurements at the mucosal zenith/base of each papilla, 3 mm apically and 6 mm apically.

area (papillae, +3 mm and +6 mm). The reference lines for the mesh grids are depicted in Fig 1. Subsequent superimposition was conducted on each immediate implant using the baseline file as reference T0 and the follow-up as test T1. Average convergence distance of < 0.1 mm values were accepted.

The cutting procedure and the distance analysis were performed with automated Geomagic Control to reduce human error during elaboration. A total of nine points were tested. Using the measures of the alveolar process at T0 and at T1, the dimensional variation ( $\Delta$ ) was expressed in absolute and relative values (in respect to the total alveolar facial process).

### Clinical Outcomes

Implant survival was evaluated clinically and radiographically at the delivery of the definitive restoration (baseline), at 6 months postloading, and at annual follow-up visits according to the criteria of Karousis et al.<sup>9</sup> Briefly, these criteria included assessment of implant mobility, signs of peri-implantitis, evaluation of patient-reported symptoms, and radiographic examination.

### Statistical Analysis

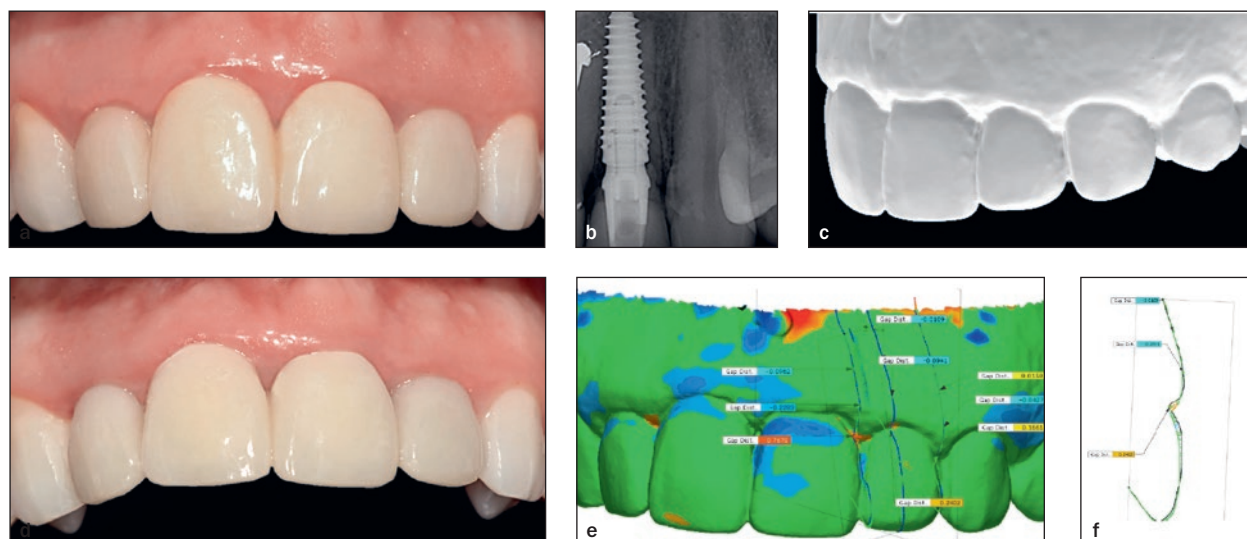
Demographic, radiographic, and clinical data are presented descriptively. Paired *t* tests were performed to assess pretherapy and posttherapy changes. A non-inferiority test was performed to assess whether the changes were noninferior to 0 (ie, no change) with a 0.5-mm clinical relevance threshold. Because of the lack of studies assessing esthetic outcomes of PDL-mediated implant placement at the time of study design and the retrospective nature of this study, a reasonable a priori power analysis was not feasible. Therefore, a convenience sample of all subjects from a previously reported cohort was analyzed (Siormpas et al)<sup>2</sup> that had both baseline and at least 3-year

**Table 2** Distribution of Included Sites

Tooth site (ADA <sup>a</sup> )	6	7	8	9	10	11
Tooth site (FDI <sup>b</sup> )	13	12	11	21	22	23
No. of sites	2	2	4	3	2	–

<sup>a</sup>American Dental Association tooth-numbering system.

<sup>b</sup>FDI tooth-numbering system.



**Fig 2** Representative case illustrating the digital evaluation workflow. (a) Baseline clinical image of implant #9. (b) Baseline periapical radiograph. (c) Model of the follow-up clinical presentation. (d) Posttreatment clinical image with angulation to depict the stable alveolar contour over time. (e) 3D rendered subtractive assessment with an embedded heatmap showing areas of change pretreatment and posttreatment. Green indicates no change, blue indicates volume gain, and orange indicates volume loss. Note the three planes of assessment, ie, mesial, midfacial, and distal depicted with blue vertical lines. (f) Midfacial cross section showing the measurements per region of interest.

follow-up casts available. Statistical analyses of the data were carried out using R statistical software (version 2.15.3, R Project).

## RESULTS

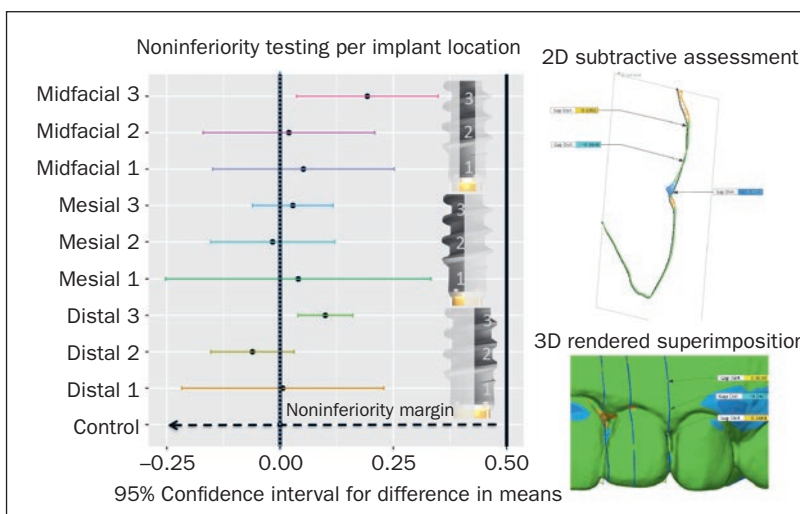
Data from 10 patients from a previously reported cohort<sup>2</sup> had complete cast records pretherapy and posttherapy and were analyzed. Specifically, the sample consisted of six female and four male participants with a median follow-up time of 55 months. Only one case with 36-month follow-up was included, while the longest follow-up was 70 months. Three of the participants had two implants fulfilling the study inclusion criteria, while the remaining seven participants contributed one implant site each to the study for a total of N = 13 sites analyzed; the site distribution of placed implants is presented in Table 2. All implants successfully maintained osseointegration during the follow-up period and demonstrated optimal soft tissue stability. In all 13 implants, the success criteria were fulfilled for a 100% success rate, with no sites exhibiting peri-implantitis. Three implants demonstrated localized bleeding on

probing without any signs of alveolar bone loss or increased probing depth from baseline. Radiographic bone levels for this population cohort have been previously reported.<sup>2</sup>

Changes during the observation period ranged from 0.19 mm (95% confidence interval [95% CI]: 0.10 to 0.28) in the midfacial region 6 mm apical to the mucosal zenith to –0.06 mm (95% CI: –0.14 to 0.02) at 5 mm apical to the base of the distal papilla midfacial at the level of the mucosal zenith (Fig 2). In general, the tissue stability was excellent at coronal and mid-root assessment planes, where it neared zero. In apical planes, such as “mid-facial 3” or “distal 3” (Fig 3), there was slightly but not significantly more remodeling approximating 0.5 mm. This is consistent with the aforementioned technique steps since the retained root section primarily occupies the coronal and mid-root areas that are critical for esthetics but not necessarily the apical extent.

The results of the noninferiority analysis revealed that all sites were within 0.5 mm of “0” difference, ie, no change from the pre-extraction baseline. This means that soft tissue changes were noninferior to “0” (Fig 3). The prespecified noninferiority margin was elected

**Fig 3** Barplot showing the 95% confidence intervals for longitudinal changes per region of interest against the noninferiority margin of 0.5 mm. In the volumetric analysis, green indicates no change, blue indicates volume gain, and orange indicates volume loss.



because of its clinical relevance. Importantly, a graded periodontal probe used for direct measurements can measure in increments of 1 mm.

## DISCUSSION

The present study assessed longitudinal labial soft tissue changes for single edentulous sites treated via PDL-mediated immediate implant placement and loading, and the results showed (1) the accomplishment of noninferior soft tissue preservation compared with no extraction, and (2) the medium-term stability of soft tissue esthetics. In brief, labial soft tissue changes after a minimum of 3 years of follow-up were consistently less than 0.5 mm compared with baseline. These results are very promising in regard to the long-term efficacy of this approach compared with conventional immediate implant placement. Although the inclusion of cases with a minimum of 2 years of follow-up only provides justification for conclusions on the medium-term performance of this technique, existing knowledge on the physiologic remodeling of the postextraction alveolus strengthens these conclusions. It is well established that the majority of ridge resorption occurs within the first 6 to 12 months postextraction and affects nearly half of the baseline alveolar ridge volume<sup>10,11</sup>; it subsequently continues at a very slow rate of approximately 0.5% of the alveolar ridge volume annually.<sup>10,11</sup> Thus, any major changes in labial soft tissue dimensions are expected to happen within the first year postextraction. This is consistent with data on tissue alterations following conventional immediate implant placement.<sup>12</sup> Based on these data, the present study included cases with a minimum of 3 years of follow-up to capture the majority of expected soft tissue alterations occurring due to partial root

extraction and showed that these changes seem to be clinically insignificant (< 0.5 mm).

Comparability to other results is limited by the lack of longitudinal human data. A large number of case reports are available but redundant, as such data are not reliable based on existing recommendations for clinical decision-making.<sup>13</sup> The only longitudinal data on soft tissue stability have been recently published by Bäumer et al and seem to be in agreement with the present findings.<sup>7</sup> In the aforementioned study, investigators followed 10 consecutively recruited participants for a mean observation time of 58 months and performed presurgery and postsurgery volumetric evaluation. The results showed that 0.34 mm was the average soft tissue change noted in the mucosal zenith area.<sup>7</sup> These results corroborate findings of the present study showing changes of less than 0.5 mm after medium-term follow-up of loaded implants with intentional root maintenance. Further comparisons to the literature are limited by the fact that the majority of clinical recommendations arise from case reports. A dearth of long-term clinical studies documenting the effectiveness of this technique, preferably in comparison to existing implant treatment approaches, is evident. Interestingly, and despite this dearth, a systematic review has already been published that included animal studies, case reports, and case series. It should be clear to clinicians who elect to offer evidence-based therapies to their patients that such a systematic review would hold a much lower position on the pyramid of evidence than a single cohort study with narrow confidence intervals such as the present one. In fact, pooling clinical studies with a low level of evidence such as case reports along with preclinical studies and reporting summary results is strongly discouraged in the medical literature, as it can create more confusion rather than guide clinical practice. The

heterogeneity of existing protocols on the use of this technique further impedes the ability to summarize existing information.

An example of the aforementioned heterogeneity ranges can be found in the varying modes of preparation of the residual tooth fragment, ie, preparation of the osteotomy through the residual root<sup>2,3</sup> or following prior removal of the lingual root component.<sup>1,7</sup> A second example is the extent and location of the retained root structure, including the preservation of a buccal root section<sup>1-3,7</sup> or a proximal root section,<sup>14</sup> the haphazard retention of a root fragment,<sup>15</sup> or the 360-degree preservation of the root circumference (anecdotal data). The former are clinical details that may have to do with clinician preference and, based on published clinical data, are not expected to lead to distinctly different clinical outcomes.<sup>2,7</sup> The latter, however, are deviations from published data that may have important ramifications for long-term treatment success. Given the recency of this treatment approach and subsequent scarceness of long-term and high short-term integration success of implant placement data, clinicians' improvisations often lead to ambiguous empirical protocols. For instance, clinicians already appear to be presenting PDL-mediated cases with 360-degree preservation of the retained root fragment. Despite the ostensible benefit of additional PDL-derived blood supply, many potential risks arise from such an approach. A reasonable biologic shortcoming would be related to the limited availability of direct contact between the implant and alveolar bone, ie, reduced osseointegration. Additional doubts arise considering the large interface that arises between the implant-retained root and alveolar bone, providing avenues for bacterial invasion in an area of dehiscence. In fact, such designs resemble the endodontic implants that were clinically used in the 1960s<sup>16</sup> and were eventually discontinued once longitudinal evidence arose documenting their shortcomings that led to many failures until evidence was sought for their use.<sup>17</sup> In the medical world, the use of surgical approaches without clinical evidence support is strictly prohibited, and implant surgery should be no exception.

It becomes evident that as this technique gains clinical ground, there is a need for randomized controlled data to support its mainstream application. Currently, the available evidence provides moderate support for its use; therefore, clinicians should exercise caution in case selection. Notably, the inclusion and exclusion criteria when reporting successful cases should be considered by clinicians. In the present patient cohort, all cases were screened for periodontitis prior to surgery, and patients with moderate or severe periodontitis and/or gingival recession at the surgical

site were excluded. Thus, the efficacy of this treatment modality for such cases is unknown, and there are no data to support PDL-mediated implant placement in periodontal patient populations. To determine whether this technique yields truly better outcomes than conventional implant placement, a highly controlled randomized controlled trial is necessary. Further, it is possible that minor discrepancies arose because of the scanning of casts versus direct intraoral scans being obtained. However, the benefit of the automated subtractive assessment performed in this study is many-fold times superior to previous assessments based on photographs or clinical measurements that are prone to examiner error.

## CONCLUSIONS

The results of this study showed that PDL-mediated immediate implant placement was not inferior to no extraction, ie, 0 mm of tissue changes. This result is of substantial clinical significance because it adds to the body of existing literature that has documented the predictability of this technique in terms of implant integration. Further, the results provide for the first time topographic characterization of tissue dimensional changes with the use of this technique; the majority of measurable clinical changes occurred in apical planes at 6 mm below the mucosal margin, which has implications for determining the length of the retained root section and better shaping technique indications.

## ACKNOWLEDGMENTS

Dr Mitsias and Dr Siormpas are the developers of the "Root Membrane Kit" that is commercially available by MegaGen Implants, Korea, and have received honoraria. MegaGen Implants had no participation in the design, analysis, or reporting of this study. The Root Membrane Group Collaborators listed in alphabetical order are as follows: Louis Bessa, DDS, Iron Formação, Portugal; Scott D. Ganz, DMD, Private Practice, Fort Lee, New Jersey, USA; Spyridon S. Gasparatos, DDS, Private Practice, Athens, Greece; Francesco G. Mangano, DMD, Department of Medicine and Surgery, Dental School, University of Varese, Italy; Isaac Tawil, DMD, Private Practice, Brooklyn, New York, USA.

## REFERENCES

1. Hürzeler MB, Zuhr O, Schupbach P, Rebele SF, Emmanouilidis N, Fickl S. The socket-shield technique: A proof-of-principle report. *J Clin Periodontol* 2010;37:855-862.
2. Siormpas KD, Mitsias ME, Kotsiotou-Siormpa E, Garber D, Kotsakis GA. Immediate implant placement in the esthetic zone utilizing the "root-membrane" technique: Clinical results up to 5 years postloading. *Int J Oral Maxillofac Implants* 2014;29:1397-1405.

3. Mitsias ME, Siormpas KD, Kontsiotou-Siormpa E, Prasad H, Garber D, Kotsakis GA. A step-by-step description of PDL-mediated ridge preservation for immediate implant rehabilitation in the esthetic region. *Int J Periodontics Restorative Dent* 2015;35:835–841.
4. Kotsakis GA, Salama M, Chrepa V, Hinrichs JE, Gaillard P. A randomized, blinded, controlled clinical study of particulate anorganic bovine bone mineral and calcium phosphosilicate putty bone substitutes for socket preservation. *Int J Oral Maxillofac Implants* 2014;29:141–151.
5. O'Neal RB, Gound T, Levin MP, del Rio CE. Submergence of roots for alveolar bone preservation. I. Endodontically treated roots. *Oral Surg Oral Med Oral Pathol* 1978;45:803–810.
6. Mitsias ME, Siormpas KD, Kotsakis GA, Ganz SD, Mangano C, Iezzi G. The root membrane technique: Human histologic evidence after five years of function. *Biomed Res Int* 2017;2017:7269467.
7. Bäumer D, Zuhr O, Rebele S, Hürzeler M. Socket Shield Technique for immediate implant placement - clinical, radiographic and volumetric data after 5 years. *Clin Oral Implants Res* 2017;28:1450–1458.
8. Calvo-Guirado JL, Troiano M, López-López PJ, et al. Different configuration of socket shield technique in peri-implant bone preservation: An experimental study in dog mandible. *Ann Anat* 2016;208:109–115.
9. Karoussis IK, Brägger U, Salvi GE, Bürgin W, Lang NP. Effect of implant design on survival and success rates of titanium oral implants: A 10-year prospective cohort study of the ITI Dental Implant System. *Clin Oral Implants Res* 2004;15:8–17.
10. Kotsakis G, Chrepa V, Marcou N, Prasad H, Hinrichs J. Flapless alveolar ridge preservation utilizing the “socket-plug” technique: Clinical technique and review of the literature. *J Oral Implantol* 2014;40:690–698.
11. Ashman A. Ridge preservation: Important buzzwords in dentistry. *Gen Dent* 2000;48:304–312.
12. Clementini M, Tiravia L, De Risi V, Vittorini Orgeas G, Mannocci A, de Sanctis M. Dimensional changes after immediate implant placement with or without simultaneous regenerative procedures: A systematic review and meta-analysis. *J Clin Periodontol* 2015;42:666–677.
13. Carrasco-Labra A, Brignardello-Petersen R, Azarpazhooh A, Glick M, Guyatt GH. A practical approach to evidence-based dentistry: X: How to avoid being misled by clinical studies' results in dentistry. *J Am Dent Assoc* 2015;146:919–924.
14. Kan JY, Rungcharassaeng K. Proximal socket shield for interimplant papilla preservation in the esthetic zone. *Int J Periodontics Restorative Dent* 2013;33:e24–e31.
15. Davarpanah M, Szmukler-Moncler S. Unconventional implant treatment: I. Implant placement in contact with ankylosed root fragments. A series of five case reports. *Clin Oral Implants Res* 2009;20:851–856.
16. Frank AL. Improvement of the crown-root ratio by endodontic endosseous implants. *J Am Dent Assoc* 1967;74:451–462.
17. Weine FS, Frank AL. Survival of the endodontic endosseous implant. *J Endod* 1993;19:524–528.