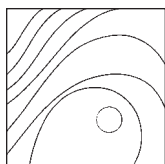


# Human Histologic Analysis of Implant Osseointegration in a Healed Site Grafted with Nondemineralized Autologous Tooth-Derived Graft Material



Snjezana Pohl, MD, DMD<sup>1</sup>  
 Hari Prasad, BS, MDT, MS<sup>2</sup>  
 Sanjana Prasad, BDS<sup>2</sup>  
 G. A. Kotsakis, DDS, MS<sup>3</sup>

*Autologous tooth-derived grafts (ATDGs) have gained popularity as bone substitute biomaterials, owing to their promising healing dynamics in vivo and to patient preference for repurposing hopeless teeth. Nonetheless, concerns exist regarding the biologic response of these ATDGs in preparation for implant placement and subsequent osseointegration. After 12 weeks of extraction socket healing, an implant with an acid-etched surface was placed using osseodensification osteotomy preparation and was retrieved after 16 weeks of integration. Histologic analysis revealed  $\geq 64\%$  of direct bone-to-implant contact at multiple regions of interest along the implant surface. Residual dentin particles were scarce and were never found in contact with the implant, suggesting that the ATDG did not interfere with implant osseointegration. Despite the overall trabecular structure of the adjacent maxillary bone with large marrow spaces, the implant surface was delineated with a continuous dense mineralized zone (thickness of 2 to 5 cell layers) with vital osteoblasts in the lacunae. These results suggest that the healing dynamics of ATDG are well aligned with implant osseointegration dynamics.* Int J Periodontics Restorative Dent 2022;42:e199–e207. doi: 10.11607/prd.4923

Human autologous tooth-derived grafts (ATDGs) were recently introduced as a source of bone substitute biomaterial.<sup>1–4</sup> Using dentin autografts in humans was first reported in 2003.<sup>5</sup> In that first report, demineralized dentin matrix granules were used as a bone substitute biomaterial for sinus augmentation.<sup>5</sup> Since then, a variety of TDGs have been introduced clinically, including block or particulate forms of tooth structures with various levels of mineralization, as shown in Fig 1.<sup>6–10</sup> In the present article, “TDG” is used as an all-encompassing term to better capture the variability of tooth-derived grafts that can contain the total root structure, dentin only, dentin and cementum, or even enamel.<sup>7,8</sup>

The introduction of a chairside procedure for processing freshly extracted teeth into nondemineralized particulate dentin has popularized the use of ATDGs.<sup>9</sup> Particulate dentin is then grafted into areas undergoing bone augmentation surgery, such as extraction sites or sinus elevation procedures.<sup>4,9</sup> Based on well-established information on the fate of various types of bone grafts and bone substitute biomaterials in the oral cavity, it is evident that even slight alterations in the composition or structure of the mineralized component of these biomaterials lead to an array of histologic and clinical

<sup>1</sup>Department of Oral Medicine and Periodontology, University of Rijeka, Rijeka, Croatia; Private Practice, Rident, Rijeka, Croatia.

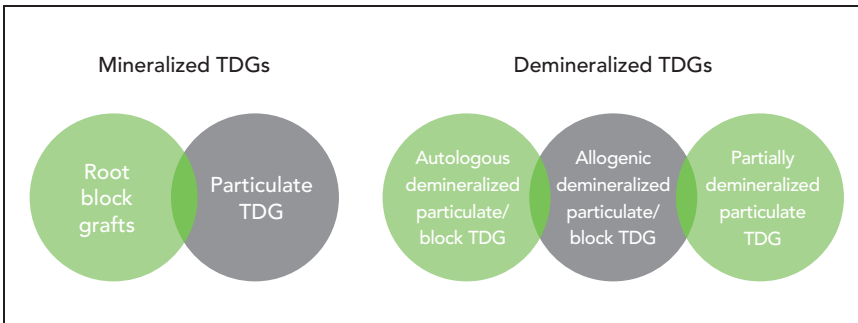
<sup>2</sup>Hard Tissue Research Laboratory, University of Minnesota, Minneapolis, Minnesota, USA.

<sup>3</sup>Department of Periodontics, University of Texas Health Science Center at San Antonio, San Antonio, Texas, USA.

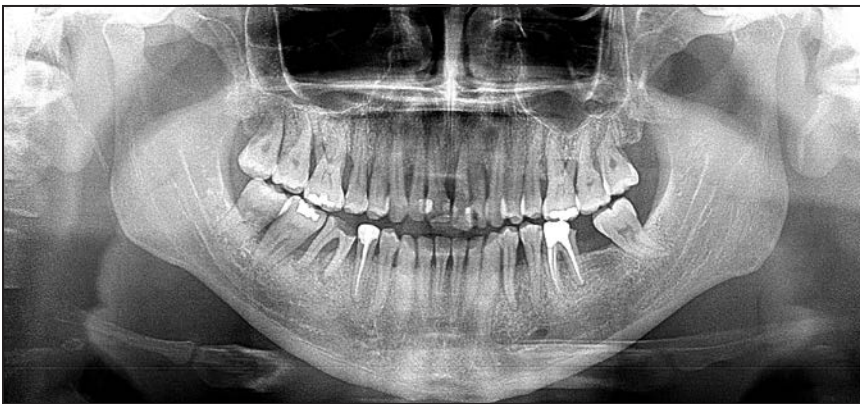Correspondence to: Dr Snjezana Pohl, Department of Oral Medicine and Periodontology at University of Rijeka, Franje Čandeka 39, Rijeka 51000, Croatia. Email: snjezana.pohl@rident.hr

Submitted March 3, 2020; accepted May 22, 2020.

©2022 by Quintessence Publishing Co Inc.



**Fig 1** Classification of currently documented tooth-derived grafts (TDGs) in dentistry.



**Fig 2** Initial radiogram of the advanced periodontal bone resorption.

responses.<sup>11</sup> These responses include rapid biomaterial degradation, resorptive substitution, and relative osteoimmunologic inactivity, as well as the presence of long-term residual particles.<sup>11,12</sup>

In order to examine the influence that the extent of dentin matrix demineralization has on bone regeneration, nondemineralized, demineralized, and partially demineralized human particulate dentin preparations were implanted in rat calvaria defects.<sup>10</sup> Microcomputed tomography images and histologic observations revealed that demineralized graft exhibited rapid resorption, while mineralized dentin

demonstrated the lowest resorption rate over 8 weeks.<sup>10</sup> Partially demineralized dentin grafts saw a greater increase in new bone formation than the remaining groups.<sup>10</sup> These findings raise a valid argument as to what the optimal resorptive substitution rate is that can enable timely implant placement in surgical sites grafted with ATDGs.

Nonetheless, current published studies have not reported whether implants placed in demineralized or nondemineralized TDG sites demonstrate failures or complications.<sup>4,13</sup> A recently published systematic review concluded that sites grafted with TDG are clinically

safe, demonstrate favorable bone forming capacity, and have adequate primary (mean ISQ: 67) and secondary (mean ISQ: 75) implant stability.<sup>14</sup> Nevertheless, it remains unclear whether nondemineralized ATDGs (ND-ATDGs) interfere with implant osseointegration and whether the structure and function of tissue regenerated by ND-ATDGs can enhance osteoblastic function and lead to new bone formation.<sup>10,15</sup> The aim of this investigation was to provide histologic evidence of implant placement and interaction with ND-ATDG in a human sample.

## Materials and Methods

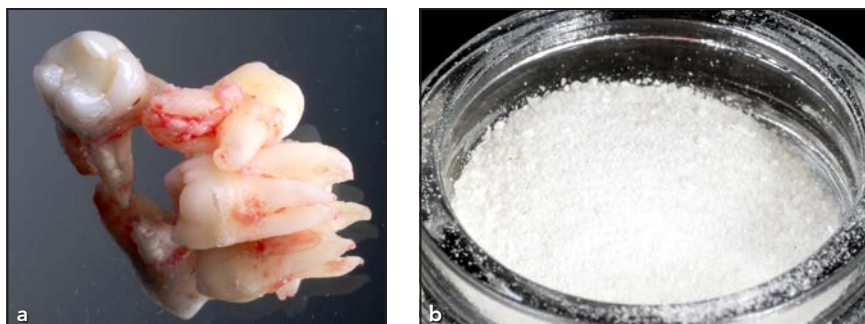### *Implant Osseointegration in an Autologous Tooth-Derived Graft*

A 49-year-old Caucasian man was treatment planned for periodontal therapy and implant rehabilitation. The treatment plan included periodontal therapy, extractions of hopeless teeth 15 to 18, 21, 22, and 26 to 28 (FDI tooth-numbering system) and regenerative periodontal surgery for sites 12 to 14 and 23 (Fig 2). Following postsurgical healing, implant placement with individual implant crowns was planned for rehabilitation of the posterior maxilla, while a conventional tooth-borne fixed dental prosthesis (FDP) was planned in the anterior maxilla. Following patient consent, extractions of teeth 15 to 17 and 26 to 28 were completed; tooth 18 was temporarily retained to facilitate support of the

removable vacuum-formed provisional restoration.

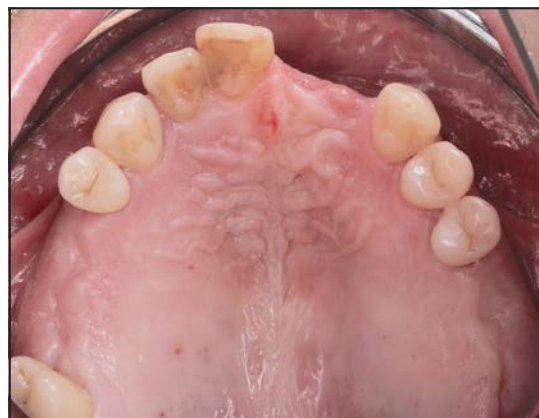At the time of extraction, the teeth were preserved and processed for ND-ATDG harvesting according to the recommendations of the dentin-grinder manufacturer.<sup>9</sup> Extracted teeth were thoroughly, mechanically cleaned using a high-speed carbide bur. All filling materials, calculus, decay, periodontal ligament, discolored dentin, and enamel were removed before processing (Fig 3a). Subsequently, cleaned roots were dried by an air syringe and ground in the sterile chamber of the dedicated autologous tooth-grinding device (Smart Dentin Grinder, KometaBio). The unit was programmed to collect particles (size: 300 to 1,200  $\mu\text{m}$ ) in the collection tray. The particulate teeth were immersed in a basic alcohol cleanser in a sterile container for 5 minutes to dissolve all organic remnants and bacteria. Subsequently, the particles were washed in sterile phosphate-buffered saline solution twice for 3 minutes each, then dried (Fig 3b). Peripheral venous blood was collected in sterile vials without anticoagulant and centrifuged for preparation of plasma-rich fibrin (PRF); this was done according to the slow centrifugation protocol (1,300 rpm for 8 minutes) and spun in a PRF centrifuge (PRF DUO centrifuge, Process for PRF).<sup>16</sup> PRF membranes were pressed in a PRF box after blood centrifugation. Sockets were grafted with particulate dentin, sealed with PRF membranes, and left to heal for 12 weeks.

After 12 weeks of healing, the ridge volume appeared well-



**Fig 3** (a) The teeth were cleaned, and (b) nondemineralized ATDG was placed (particle size: 300 to 1,200  $\mu\text{m}$ ).

**Fig 4** Clinical appearance 12 weeks after tooth extractions and ND-ATDG grafting.



maintained, and a clinical examination confirmed a sufficient amount of keratinized gingiva at the implant sites (Fig 4). CBCT imaging revealed sufficient ridge dimensions for implant placement, with a minimum coronal ridge width of 7 mm at the implant sites (Fig 5). Because of patient concerns regarding tooth 14's mobility and sensitivity, a decision was made to extract the tooth and place an implant.

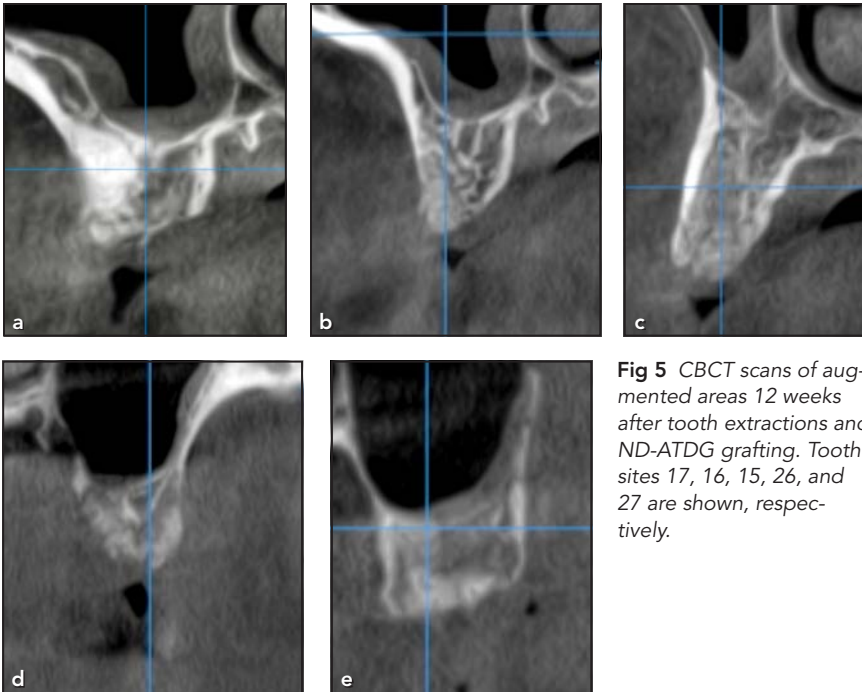
At the time of implant placement, the sites previously grafted with dentin showed clinical density of D2 to D3 bone. Implant osteotomies were prepared under copious irrigation following the osseoden-

sification protocol and specialized burs (Versah) (Fig 6a).

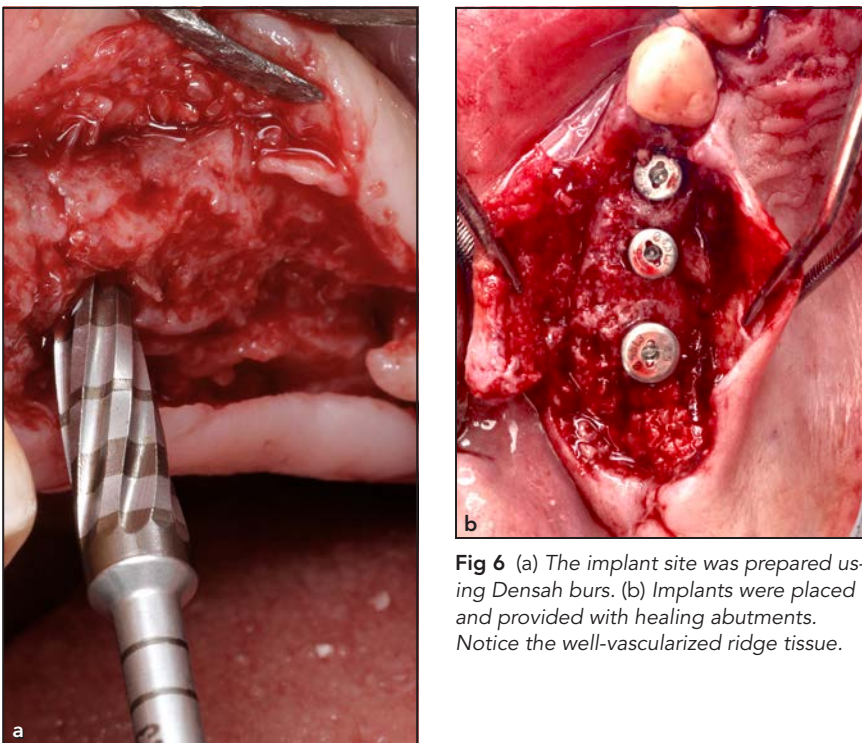
Implants with an acid-etched surface (RSX Semados, Bego) were placed and provided with profile healing abutments (3 to 5 mm) for transgingival healing (Fig 6b).

After 16 weeks of uneventful healing, that patient presented for restorative treatment. Because of a change in the patient's financial situation, the restorative treatment plan was modified; instead of individual FDPs for implants at sites 14 to 16, an implant-supported FDP was planned to reduce costs. The option to either submerge the implant at site 15 underneath the pontic site or explant it was discussed with the





**Fig 5** CBCT scans of augmented areas 12 weeks after tooth extractions and ND-ATDG grafting. Tooth sites 17, 16, 15, 26, and 27 are shown, respectively.



**Fig 6** (a) The implant site was prepared using Densah burs. (b) Implants were placed and provided with healing abutments. Notice the well-vascularized ridge tissue.

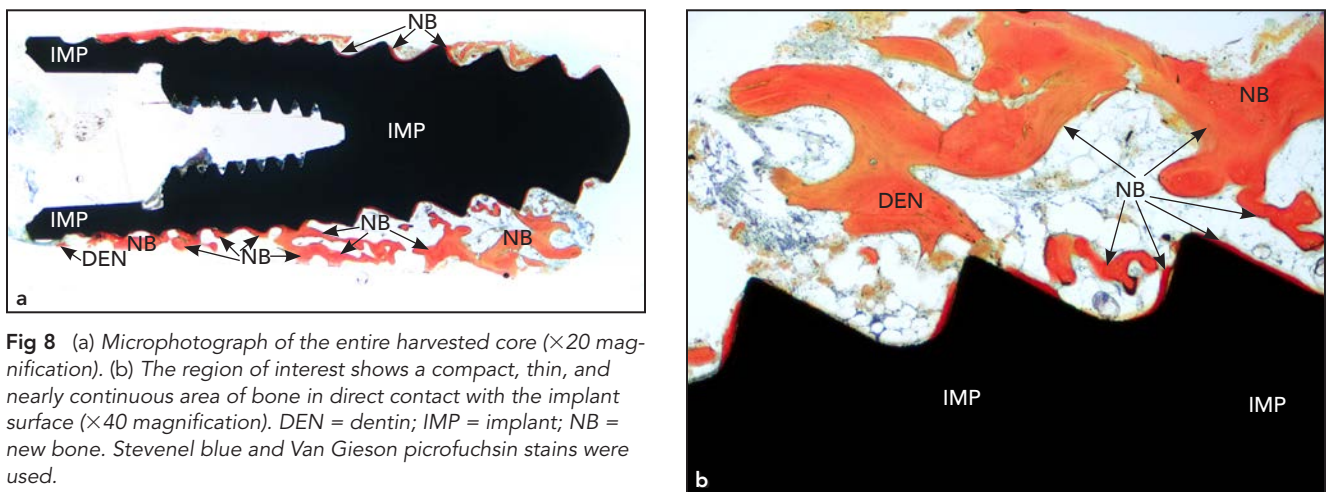
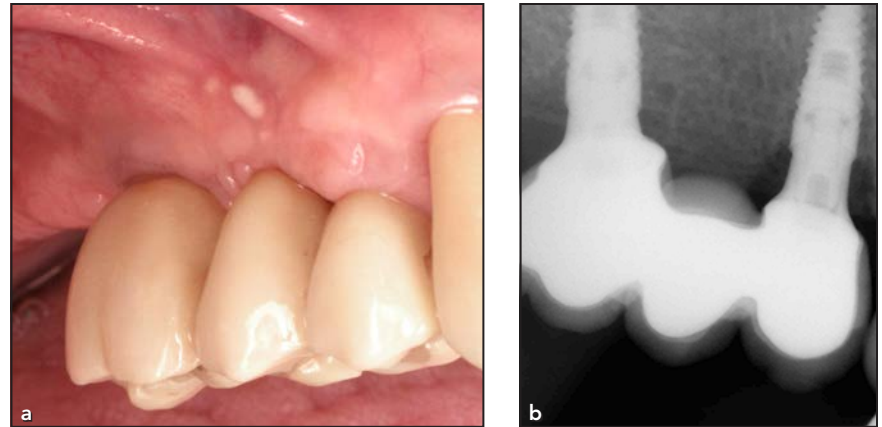
patient and restorative dentist, and the patient opted for explantation. The implant was retrieved using a hollow trephine (4.5-mm internal diameter) without compromising the buccal or lingual bone plates. The resulting defect was augmented with biphasic calcium-sulfate-composite bone graft cement (Bond Apatite, Augma Biomaterials). With the patient's written consent, the implant and surrounding tissue were preserved in 10% neutral buffered formalin and submitted for histologic and histomorphometric analyses to the Hard Tissue Research Laboratory at the University of Minnesota. The histologic preparation protocol has previously been described in detail.<sup>17</sup> In brief, tissues were dehydrated and embedded in resin followed by nondecalcified sectioning. Sections were then stained with Stevenel blue and Van Gieson picrofuchsin. Following uneventful healing, the patient was provided with a final prosthesis (Fig 7).

## Results

### *Histologic Outcomes of Osseointegration in ND-ATDG*

Implant placement progressed uneventfully at all sites, and no adverse events were recorded. The retrieved implant appeared clinically osseointegrated at the time of explantation and resisted percussion or any movement prior to harvesting. After sectioning the implant-bone core and histologic staining, bright-field microscopy ( $\times 20$  magnification) revealed a continuous zone of bone

**Fig 7** (a) Clinical and (b) radiographic views after delivery of the definitive prosthesis.



**Fig 8** (a) Microphotograph of the entire harvested core ( $\times 20$  magnification). (b) The region of interest shows a compact, thin, and nearly continuous area of bone in direct contact with the implant surface ( $\times 40$  magnification). DEN = dentin; IMP = implant; NB = new bone. Stevenel blue and Van Gieson picrofuchsin stains were used.

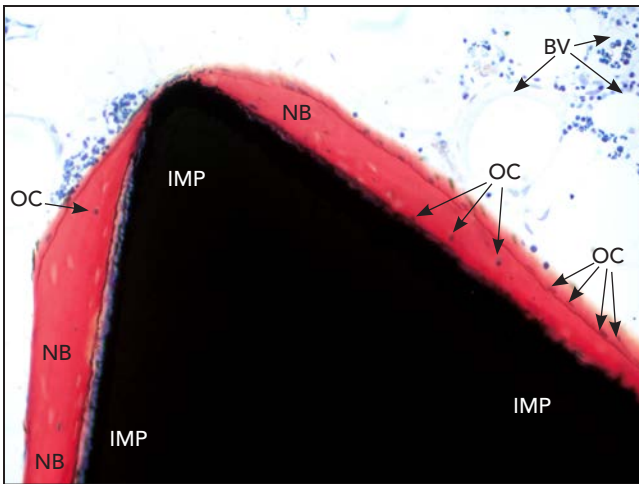
deposition in the periphery of the implant (Fig 8a). Limited dentin particles remained in the vicinity of the implant but not in direct contact and were integrated in well-mineralized newly formed bone (Fig 8b). Under high magnification ( $\times 200$ ), the continuous bone-to-implant contact (BIC) zone appeared to be 2 to 5 cells thick, and the deposited bone appeared to be in direct contact with the implant surface, consistent with true osseointegration (Fig 9). The exact percentage of BIC was assessed histomorphometrically at four regions

of interest ( $\times 40$  magnification) and found to range from 64% (in the apical right side of the implant) to 93% (in the apical left side), with an average BIC of 75%. The mineralized-tissue BIC was complete due to osseous tissue contact, with no areas of direct dentin integration (Fig 10).

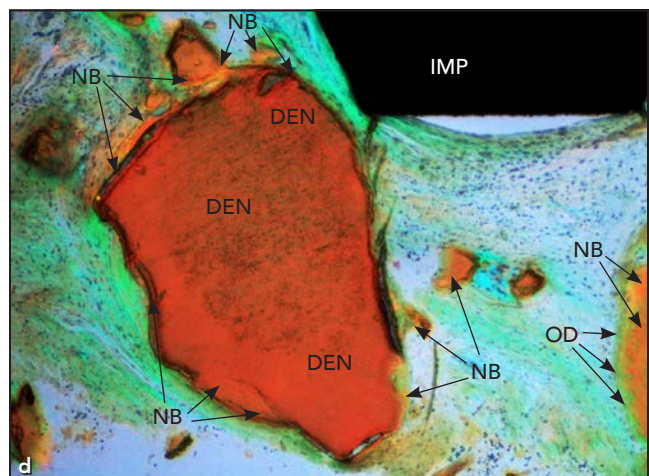
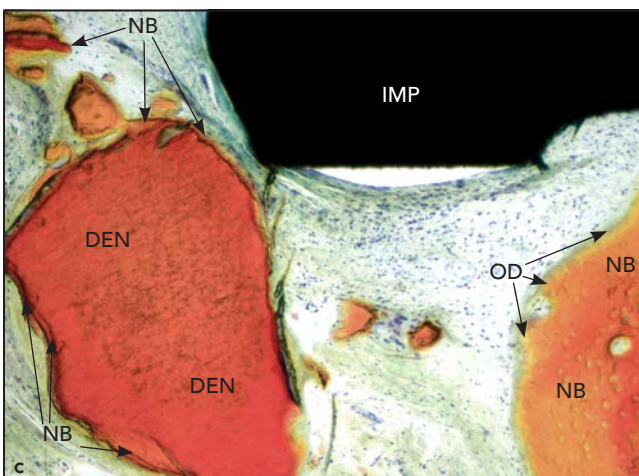
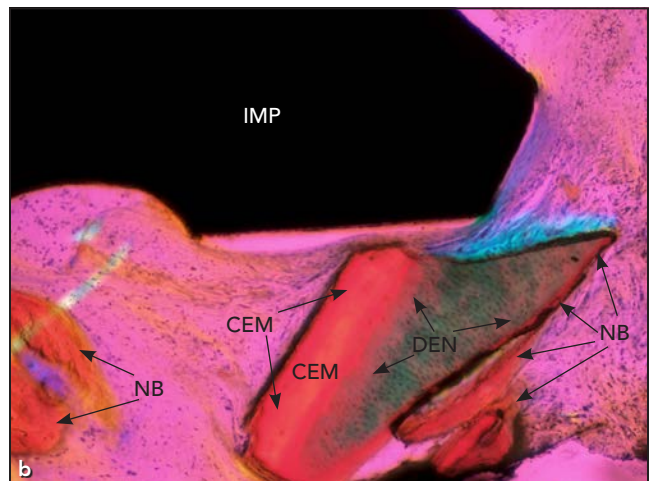
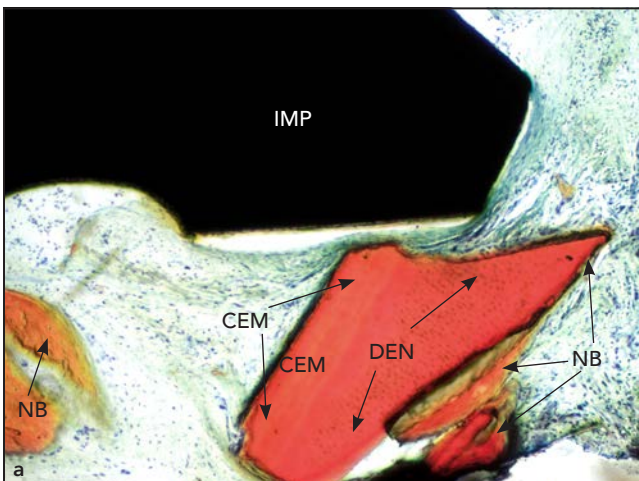
Two features that appear under high magnification (Fig 9) are of interest. First, the lacunae are filled with cells, indicative of live new bone in contact with the implant. Second, an incremental line is observed that appears to have

the features of dentin. This nearly resorbed dentin surface in an estimated distance of  $< 10 \mu\text{m}$  from the implant surface suggests that part of the implant body was in contact with dentin particles and that, during the 18-week healing, creeping substitution took place with replacement by new vital bone. The polarized microscopy assessment (Fig 10) exhibits early organization of collagen fibers, with a linear orientation in the majority of the surface area. A few areas that are not near the implant surface still show signs of immature





**Fig 9** A high-magnification microphotograph shows viable osteocytes in the region of osseointegration ( $\times 200$  magnification). BV = blood vessels; IMP = implant; NB = new bone; OC = osteocyte. Stevenel blue and Van Gieson picrofuchsin stains were used.



**Fig 10** Microphotographs of two residual tooth-derived graft particles (a and c) and corresponding polarized microscopic images (b and d, respectively) that highlight the tubular dentin ( $\times 100$  magnification for all images). Note that these particles are in proximity to, but not in direct contact with, the implant. CEM = cementum; DEN = dentin; IMP = implant; NB = new bone; OD = osteoid. Stevenel blue and Van Gieson picrofuchsin stains were used.

woven bone structure, consistent with bone maturation in progress.

## Discussion

Autogenous bone grafting is regarded as the gold standard for bone augmentation because it carries viable and nonviable osteoblasts and osteocytes. These cells contribute to its excellent osteoinductivity and render an osteogenic potential. Further, autogenous bone has favorable scaffolding properties because of its organic collagen structure, composed primarily of collagen types I and III, that is conducive to the homing and proliferation of osteoblast progenitors.<sup>18,19</sup> However, concerns exist regarding its high resorption rates when used as the sole graft biomaterial.<sup>20</sup> In the present case, using mineralized ATDG showed an exquisite balance between its resorption and bone formation, which is consistent with previous histologic findings.<sup>4</sup> The dimensional stability of ND-ATDG seems to be favorable and supportive of both bone growth and dimensional stability maintenance. Recently published human data from a CBCT study showed a mean reduction of  $0.87 \pm 0.84$  mm in the coronal level of the buccal bone plate 4 months after socket grafting with ND-ATDG. In the same study, slight gains in the vertical dimension were noted at the midbuccal and midlingual areas, averaging 1.1% and 5.6%, respectively.<sup>3</sup> These findings are commensurate with the realization that an ideal scaffold material should not only maintain the

ridge volume but also have controlled resorption and be replaced by vital bone in a timely manner.<sup>11,12</sup> Results of the present case study invariably demonstrate that dentin was rapidly resorbed within the 28 weeks from the time of extraction and ridge preservation to implant integration, and the limited remaining dentin and cementum structure was bridged with vital new mineralized bone. The growth of bone on residual dentin was likely due to a resorptive substitution because of the inseparable appearance (seen at a low magnification) and the areas of reversal (seen at very high magnifications;  $\times 100$  to  $\times 200$ ) at the interface between the two.

The degree of osteoconductivity of mineralized scaffolds is highly dependent on their porosity. The degree of porosity and its disposition directly influence the biologic behavior of biomaterial grafts. In an *ex vivo* experiment, it was shown that mineralized dentin particles present intra- and interparticle porosity, resulting in a much larger volume of tooth matter after grinding when compared to block tooth volume.<sup>21</sup> This porosity increases space for new vessel growth, supporting healing and replacement resorption to achieve lamellar bone.

Autologous dentin is shown to induce bone deposition directly on its surface and undergo replacement resorption. Two recent pilot clinical studies have highlighted the healing dynamics of ND-ATDG in the alveolar ridge environment. First, Mazor et al<sup>4</sup> assessed the temporal healing dynamics of ND-ATDG (which the authors referred

to as “autologous tooth structure”). A variable reentry time design showed that at 3.5 months post-grafting, the majority of ND-ATDG was substituted by new vital bone, with early signs of lamellar organization across the socket surface.<sup>4</sup> Notably, postextraction dentin particles—but not residual enamel particles—were interconnected in direct contact with new woven bone as early as 3 months.<sup>4</sup> Another clinical study found a progressive increase in the proportion of bone with a decrease in the proportion of dentin at 4, 5, and 6 months after ND-ATDG/PRF grafting.<sup>1</sup> The fact that dentin particles emerged as the focus of new bone formation during early healing is in corroboration with evidence that demineralized dentin has osteopromotive and possibly osteoinductive properties, which promote osteoblastic proliferation and early differentiation via TGF- $\beta 1$  transduction.<sup>22</sup> While this is true for acid-demineralized dentin (which is not convenient for chairside treatment due to concerns with acid adsorption and cytotoxicity), an *ex vivo* study by Schwartz et al<sup>15</sup> suggests that dentin demineralization by osteoclasts during remodeling shows osteopromotive effects similar to tetracycline-hydrochloric acid demineralization.<sup>15</sup>

The present histologic results showed adequate BIC and a compact, thin layer of bone across the entire implant. In comparison, Froum et al reported a wide range of BIC, from 40% to 72%, for osseointegration in humans.<sup>23</sup> The present case of ND-ATDG placement in a postextraction socket in

combination with PRF bears some resemblance to Carmagnola et al, who assessed bone healing in canine dental arch defects augmented with inorganic bovine bone mineral with a fibrin sealant.<sup>24</sup> In their work, Carmagnola et al found that although implants clinically integrated in sites previously treated with inorganic bovine bone mineral, the presence of residual graft particles hindered any BIC within the augmented portion of the sockets.<sup>24</sup> This comparison provides a plausible explanation to the present study's findings of high BIC, marked by the high degree of resorptive substitution of the ND-ATDG and no residual particles left in the bone-implant interface. Nevertheless, the fact that PRF was employed in conjunction with ND-ATDG must be interpreted with caution, as PRF has a known accelerating effect in both soft tissue and bone healing in postextraction sites, which may have improved the healing dynamics of ND-ATDG.<sup>25</sup> Further studies with appropriate controls are necessary to provide more granular information on the turnover rate of ND-ATDG.

## Conclusions

A recent narrative review from the 2019 Proceedings of the European Workshop of Periodontology concluded that: "The ideal bone graft in the future will likely contain a combination of biomaterials with varying features that can control mechanical properties, pore morphology, interconnective pores, surface structure, release of active bone-promoting

biomolecules, and controlled biodegradability, which ensures resorption during the tissue-remodeling process while maintaining the defect volume for bone ingrowth."<sup>26</sup> Results from the present use of ND-ATDG are supportive of several of these features being characteristics of ND-ATDG and support that ND-ATDG is compatible with implant biomaterial placement. While the present study and other recently published data<sup>1-4</sup> support that ND-ATDG has favorable properties for alveolar bone regeneration and a strong potential for clinical use, further research is required to provide comparative data, preferably to autogenous bone.

## Acknowledgments

The authors declare no conflicts of interest.

## References

- Andrade C, Camino J, Nally M, Quirynen M, Martínez B, Pinto N. Combining autologous particulate dentin, L-PRF, and fibrinogen to create a matrix for predictable ridge preservation: A pilot clinical study. *Clin Oral Investig* 2020;24:1151-1160.
- Cardaropoli D, Nevins M, Schupbach P. New bone formation using an extracted tooth as a biomaterial: A case report with histologic evidence. *Int J Periodontics Restorative Dent* 2019;39:157-163.
- Pohl S, Binderman I, Tomac J. Maintenance of alveolar ridge dimensions utilizing an extracted tooth dentin particulate autograft and platelet-rich fibrin: A retrospective radiographic cone-beam computed tomography study. *Materials (Basel)* 2020;13:1083.
- Mazor Z, Horowitz RA, Prasad H, Kotsakis GA. Healing dynamics following alveolar ridge preservation with autologous tooth structure. *Int J Periodontics Restorative Dent* 2019;39:697-702.
- Murata M. Autogenous demineralized dentin matrix for maxillary sinus augmentation in humans: The first clinical report [abstract]. First International Association for Dental Research (IADR/PER General Session), 25-28 Jun 2003, Göteborg, Sweden. International Association for Dental Research.
- Schwarz F, Golubovic V, Mihatovic I, Becker J. Periodontally diseased tooth roots used for lateral alveolar ridge augmentation. A proof-of-concept study. *J Clin Periodontol* 2016;43:797-803.
- Kim YK, Um IW, Murata M. Tooth bank system for bone regeneration—Safety report. *J Hard Tissue Biol* 2014;23:371-376.
- Kim YK, Lee J, Um IW, et al. Tooth-derived bone graft material. *J Korean Assoc Oral Maxillofac Surg* 2013;39:103-111.
- Binderman I, Hallel G, Nardy C, Yaffe A, Sapoznikov L. Processing extracted teeth for immediate grafting of autogenous dentin. *Implant Practice US* 2014;8:43-46.
- Bartee BK. Extraction site reconstruction for alveolar ridge preservation. Part 1: Rationale and materials selection. *J Oral Implantol* 2001;27:187-193.
- Kotsakis GA, Salama M, Chrepa V, Hinrichs JE, Gaillard P. A randomized, blinded, controlled clinical study of particulate anorganic bovine bone mineral and calcium phosphosilicate putty bone substitutes for socket preservation. *Int J Oral Maxillofac Implants* 2014;29:141-151.
- Koga T, Minamizato T, Kawai Y, et al. Bone regeneration using dentin matrix depends on the degree of demineralization and particle size. *PLoS One* 2016;11:e0147235.
- Minamizato T, Koga T, Takashi I, et al. Clinical application of autogenous partially demineralized dentin matrix prepared immediately after extraction for alveolar bone regeneration in implant dentistry: A pilot study. *Int J Oral Maxillofac Surg* 2018;47:125-132.
- Gual-Vaqués P, Polis-Yanes C, Estrugo-Devesa A, Ayuso-Montero R, Mari-Roig A, López-López J. Autogenous teeth used for bone grafting: A systematic review. *Med Oral Patol Oral Cir Bucal* 2018;23:e112-e119.
- Schwartz Z, Lohmann CH, Wieland M, et al. Osteoblast proliferation and differentiation on dentin slices are modulated by pretreatment of the surface with tetracycline or osteoclasts. *J Periodontol* 2000;71:586-597.



16. Fujioka-Kobayashi M, Miron RJ, Hernandez M, Kandalam U, Zhang Y, Choukroun J. Optimized platelet-rich fibrin with the low-speed concept: Growth factor release, biocompatibility, and cellular response. *J Periodontol* 2017;88:112–121.
17. Kotsakis GA, Joachim FPC, Saroff SA, Mahesh L, Prasad H, Rohrer MD. Histomorphometric evaluation of a calcium-phosphosilicate putty bone substitute in extraction sockets. *Int J Periodontics Restorative Dent* 2014;34:233–239.
18. Romanos GE, Bernimoulin JP. Collagen as a basic element of the periodontium: Immunohistochemical aspects in the human and animal. 1. Gingiva and alveolar bone [in German]. *Parodontol* 1990;1:363–375.
19. Sakkas A, Wilde F, Heufelder M, Winter K, Schramm A. Autogenous bone grafts in oral implantology—Is it still a “gold standard”? A consecutive review of 279 patients with 456 clinical procedures. *Int J Implant Dent* 2017;3:23.
20. Cansiz E, Haq J, Manisali M, Cakarer S, Gultekin BA. Long-term evaluation of three-dimensional volumetric changes of augmented severely atrophic maxilla by anterior iliac crest bone grafting. *J Stomatol Oral Maxillofac Surg* 2020;121:665–671.
21. Calvo-Guirado JL, Ballester-Montilla A, De Aza, PN, et al. Particulated, extracted human teeth characterization by SEM-EDX evaluation as a biomaterial for socket preservation: An in vitro study. *Materials (Basel)* 2019;12:380.
22. Bègue-Kirn C, Smith AJ, Ruch JV, et al. Effects of dentin proteins, transforming growth factor beta 1 (TGF beta 1) and bone morphogenetic protein 2 (BMP2) on the differentiation of odontoblast in vitro. *Int J Dev Biol* 1992;36:491–503.
23. Froum SJ, Simon H, Cho SC, Elian N, Rohrer MD, Tarnow DP. Histologic evaluation of bone-implant contact of immediately loaded transitional implants after 6 to 27 months. *Int J Oral Maxillofac Implants* 2005;20:54–60.
24. Carmagnola D, Berglundh T, Araújo M, Albrektsson T, Lindhe J. Bone healing around implants placed in a jaw defect augmented with Bio-Oss. An experimental study in dogs. *J Clin Periodontol* 2000;27:799–805.
25. Kotsakis GA, Boufidou F, Hinrichs JE, Prasad HS, Rohrer M, Tosios KI. Extraction socket management utilizing platelet rich fibrin: A proof-of-principle study of the “accelerated-early implant placement” concept. *J Oral Implantol* 2016;42:164–168.
26. Sanz M, Dahlin C, Apatzidou D, et al. Biomaterials and regenerative technologies used in bone regeneration in the craniomaxillofacial region: Consensus report of group 2 of the 15th European Workshop on Periodontology on Bone Regeneration. *J Clin Periodontol* 2019;46(suppl 21):s82–s91.