



Steps 1 - 2

Remove the crown to assess whether or not cement residues are present on the implant surface. **If present, there is a 75% chance for successful treatment using this protocol.¹**

If possible to retrieve the crown, primary closure is preferable for regeneration. Replace the crown with a sterile (not a sterilized or re-used) cover screw to aid in gingival augmentation.² This is a critical step for ensuring there is enough tissue growth after 3-4 weeks to achieve passive primary closure. If the cover screw is exposed during healing, immediately replace with a healing abutment or the replaced crown using a second stage procedure to avoid food impaction and infections.

Step 3

Mechanical contact non-abrasive (e.g. nylon brushes) and **mechanical non-contact** (e.g. pressurized waterjet) means of implant surface cleaning offer the best balance between gentle biofilm removal and preservation of titanium biocompatibility.³

Use a solution of 1 part NaOCl (Sodium Hypochlorite) to 5 parts sterile water only in areas where the titanium surface is exposed in the sulcus. Applied with gentle burnishing with a gauze, NaOCl has a minor surface oxide alteration effect but it does not kill osteoprogenitor cells.⁴

CAUTION: Using titanium brushes or curettes on implant areas that will be grafted is not advised. Metal to titanium contact results in permanent removal of the passivation layer and causes the loss of cytocompatibility.⁵ Chlorhexidine is not recommended for use on implant surfaces because it prevents the cells from reattaching which results in failed regeneration.

Step 4

Apply ample irrigation followed by grafting of the area with an Osteostimulative or Osteoinductive biomaterial⁶ (NovaBone® Morsels), which is then covered with a collagen membrane (Zmatrix™, Osteogenics).

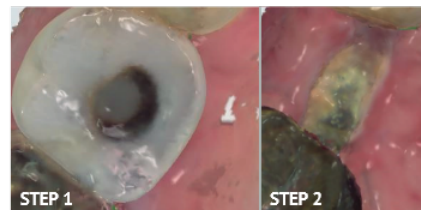
Primary closure should be achieved relatively easily as the site was previously prepped with a soft tissue augmentation. If the crown was not removed, proceed with secure closure by adding a sling suture around the crown for increased clot stabilization.

Step 5

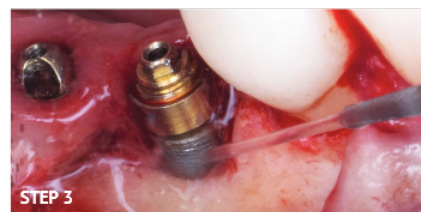
Allow 4-6 months for healing without probing. Recommend water irrigation with a waterpik for home care after initial healing (4 weeks), then assess radiographically. If the site in question is regenerated, replace the restoration, and complete oral hygiene without the use of Fluoride. Fluoride is electronegative and can corrode titanium.

Featured Products:

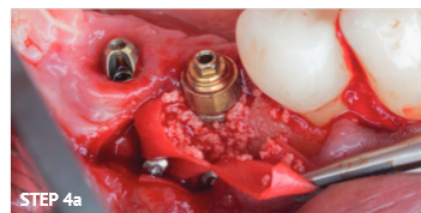
► NovaBone® Dental Morsels ► Zmatrix™



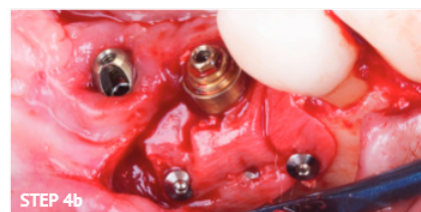
Intraoral scan images prior to crown removal (Fig. 1 - see access hole created with a diamond bur), and 3 weeks after healing with substantial increase in keratinized tissue over the cover screw



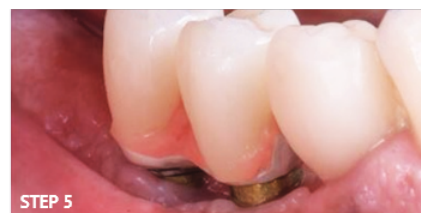Implant surface decontamination - the most critical part of the entire procedure. Implant-specific cleaning approach



Membrane tacked into place for stability then packed with 0.5cc NovaBone® Morsels



Membrane secured



Replaced and recontoured restorations to allow proper hygiene in place at 4-months post-healing. The tissue is now healthier with probing depths < 5 mm.

1. The positive relationship between excess cement and peri-implant disease: a prospective clinical endoscopic study. *J Periodontol.* 2009 Sep;80(9):1388-92. 2. Spontaneous in situ gingival augmentation. *Langer B. Int J Periodontics Restorative Dent.* 1994 Dec;14(6):524-35. 3. Strategies for implant surface decontamination in peri-implantitis therapy. *Int J Oral Implantol (Berl).* 2022 Sep 9;15(3):213-248. Monje A, Amerio E, Kook Cha J, Kotsakis G, Pons R, Renvert S, Sanz-Martin I, Schwarz F, Sculean A, Stavropoulos A, Tarnow D, Wang HL. 4. Increased Levels of Dissolved Titanium Are Associated With Peri-Implantitis - A Cross-Sectional Study. *Safoti LM, Kotsakis GA, Pozhizkov AE, Chung WO, Daubert DM. J Periodontol.* 2017 May;88(5):436-442. 5. Antimicrobial Agents Used in the Treatment of Peri-Implantitis Alter the Physicochemistry and Cytocompatibility of Titanium Surfaces. *Kotsakis GA, Lan C, Barbosa J, Lill K, Chen R, Rudney J, Aparicio C. J Periodontol.* 2016 Jul;87(7):809-19. 6. Osteostimulative calcium phosphosilicate biomaterials partially restore the cytocompatibility of decontaminated titanium surfaces in a peri-implantitis model. *Karoussis IK, Kyriakidou K, Papaparaskevas J, Vrotsos IA, Simopoulou M, Kotsakis GA. J Biomed Mater Res B Appl Biomater.* 2018 Oct;106(7):2645-2652