

# A Randomized, Blinded, Controlled Clinical Study of Particulate Anorganic Bovine Bone Mineral and Calcium Phosphosilicate Putty Bone Substitutes for Socket Preservation

Georgios A. Kotsakis, DDS<sup>1</sup>/Maurice Salama, DMD<sup>2</sup>/Vanessa Chrepa, DDS<sup>3</sup>/  
James E. Hinrichs, DDS, MS<sup>4</sup>/Philippe Gaillard, PhD<sup>5</sup>

**Purpose:** The purpose of this study was to compare the clinical efficacy of an anorganic bovine bone graft particulate to that of a calcium phosphosilicate putty alloplast for socket preservation. **Materials and Methods:** Thirty teeth were extracted from 24 patients. The sockets were debrided and received anorganic bovine bone mineral (BOV, n = 12), calcium phosphosilicate putty (PUT, n = 12), or no graft (CTRL, n = 6). The sockets were assessed clinically and radiographically 5 months later. Eight sockets in the BOV group and nine in the PUT group received implants 5 to 6 months postgrafting. The maximum implant insertion torque (MIT) was measured as an index of primary implant stability. The data were analyzed with the Mann-Whitney test. **Results:** Both test groups had statistically significantly less reduction in mean ridge width (BOV:  $1.39 \pm 0.57$  mm; PUT:  $1.26 \pm 0.41$  mm) in comparison to the control group ( $2.53 \pm 0.59$  mm). No statistically significant difference was identified between the test groups. MIT for PUT was  $\leq 35$  N/cm<sup>2</sup> (MIT grade 4) for seven of the nine implants. MIT values in the BOV group ranged from grade 1 (10 to 19 N/cm<sup>2</sup>) to grade 4, which was statistically significantly lower than for the PUT group. The overall implant success rate was 94.1% (16 of 17 implants were successful). No implants were lost in the PUT group; one implant failed in the BOV group. **Conclusion:** Both tested bone substitutes can be recommended for preservation of alveolar ridge width following extraction. PUT might be more suitable for achieving primary stability for implants placed at 5 to 6 months postextraction. INT J ORAL MAXILLOFAC IMPLANTS 2014;29:141–151. doi: 10.11607/jomi.3230

**Key words:** socket preservation, bone graft, dental putty, tooth extraction, primary implant stability, insertion torque

Following tooth extraction, the socket undergoes physiologic resorption of the alveolar bone as part of the healing process.<sup>1,2</sup> Previous publications have

shown that early bone loss can be significantly reduced by employing socket preservation procedures.<sup>3,4</sup> Alloplastic bone substitutes and xenografts have been used successfully for socket preservation procedures.<sup>5,6</sup> However, each bone substitute displays a different resorption rate. Clinicians should be aware of the rate of new bone formation that each graft material stimulates, as well as the subsequent replacement of the graft material by host bone through the mechanism of creeping substitution, so that sufficient time is allowed for socket healing before implant placement.<sup>7</sup>

Calcium phosphosilicate (CPS) putty is a newly formulated material that is approved for bone repair and regeneration in dental osseous defects. It is a premixed composite of 70% calcium phosphosilicate particulate and 30% synthetic absorbable binder.<sup>8</sup> In vitro data suggest that the material is bioactive, and the bioactivity begins when the active ingredient interacts with blood.<sup>9</sup> This graft material has demonstrated an ability to adhere to normal bone and help in clot stabilization.<sup>10</sup> The bioactivity of CPS results from the chemical

<sup>1</sup>Resident, Advanced Education Program in Periodontology, University of Minnesota, Minneapolis, Minnesota, USA.

<sup>2</sup>Private Practice, Atlanta, Georgia, USA.

<sup>3</sup>Resident, Advanced Education Program in Endodontics, University of Texas Health Science Center, San Antonio, Texas, USA.

<sup>4</sup>Professor and Director, Advanced Education Program in Periodontology, University of Minnesota, Minneapolis, Minnesota, USA.

<sup>5</sup>Research Associate, Clinical and Translational Research Institute, University of Minnesota, Minneapolis, Minnesota, USA.

**Correspondence to:** Georgios A. Kotsakis, Advanced Education Program in Periodontology, University of Minnesota, 515 Delaware Street SE Minneapolis, MN 55455, USA. Email: kotsa001@umn.edu

©2014 by Quintessence Publishing Co Inc.

release of ionic dissolution products—silicon, sodium, calcium, and phosphate—and has been shown to stimulate multiple generations of undifferentiated cells into osteoblasts.<sup>11,12</sup>

CPS putty is available in a cartridge delivery system that simplifies the delivery process and eliminates any need to handle the graft material prior to placement. It has been used successfully in various osseous defects, with no reported adverse events.<sup>8,13</sup> Putty products also enjoy a significant handling advantage over particulate grafts. A study by Vance et al reported that a putty bone substitute displayed simpler placement and enhanced particle containment in comparison to a particulate xenograft.<sup>14</sup>

Anorganic bovine bone mineral (ABBM) is a porous xenogeneic particulate graft that exhibits osteoconductive properties. It has a long history of use in oral surgery and has been found to be safe and effective for alveolar ridge augmentation and preservation procedures.<sup>15,16</sup> ABBM exhibits delayed resorption, with residual graft particles seen as late as 4 years postimplantation.<sup>17,18</sup> The effect of the remaining particles in healed sites on the degree of osseointegration of implants placed in these sites is unclear. Carmagnola et al reported that, in an animal study, all implants placed in defects previously augmented with ABBM failed to osseointegrate within 3 months.<sup>19</sup> On the other hand, it has been well documented that, although the ABBM particles remain at the defect site for a prolonged period of time, they are surrounded by vital, newly formed bone that undergoes physiologic remodeling and integration.<sup>20</sup> Berglundh and Lindhe found in an animal study that a zone of vital host bone separated the ABBM particles from the implant surface, suggesting that these particles have no negative effect on the osseointegration of implants.<sup>21</sup> The clinical question that remains unanswered is whether the xenograft particles in the extraction socket have any effect on the timing of implant placement, and whether predictable osseointegration is possible. While several studies have histologically and histomorphometrically evaluated bone after the healing of grafted extraction sockets, there are very few reports that discuss the clinical attributes of the grafted bone in those sites.

The quality of augmented bone in the extraction socket determines the maximum insertion torque that can be obtained during implant placement.<sup>22,23</sup> It has been shown that the quality and quantity of bone available at the implant site are critical local factors in determining the success of dental implants.<sup>24</sup>

The purpose of this randomized, controlled clinical study was to quantify and compare bone dimensions associated with extraction sockets that were grafted with either ABBM (Bio-Oss, Osteohealth) or CPS (NovaBone Dental Putty, NovaBone Products) at 5 to 6

months after grafting. Clinical measurements, including alterations in ridge dimensions and maximum implant insertion torque values, were the estimated outcomes.

## MATERIALS AND METHODS

Twenty-six consecutive patients requiring a total of 32 extractions were enrolled in this study. Seventeen men and nine women ranging in age from 21 to 68 years were randomly assigned to receive grafting with ABBM plus a collagen plug (BOV), CPS plus a collagen plug (PUT), or extraction alone (CTRL). Following a thorough oral evaluation, patients were informed about the diagnosis and treatment alternatives. Willing participants signed the consent form and were enrolled in the study. The study was conducted in accordance with the Helsinki Declaration of 1975, as revised in 2000. Adult patients were included in this study if they were treatment planned for extraction of a single tooth and had no systemic diseases that could affect the outcome of treatment.

Exclusion criteria were:

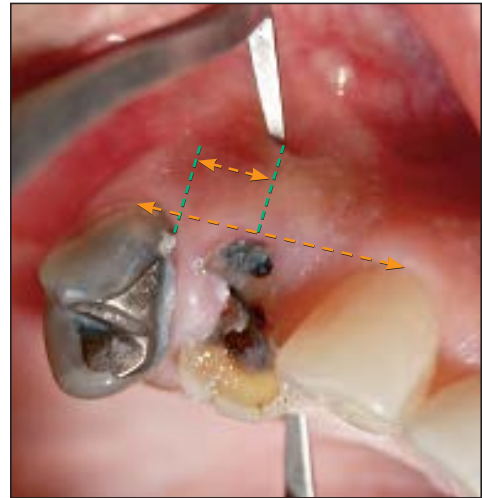
- Medical history that contraindicated oral surgical treatment
- Chronic therapy with nonsteroidal anti-inflammatory drugs, bisphosphonates, and/or corticosteroids
- Pregnancy
- Severe periodontal disease
- Prior mucogingival or periodontal surgery at the experimental site
- Loss of more than 50% of the buccal plate at the time of extraction
- Heavy smoking (> 10 cigarettes/day)

Subjects who smoked fewer than 10 cigarettes per day were included in the study, and they were encouraged to abstain from smoking beginning a week before surgery and continuing for 4 weeks after surgery.

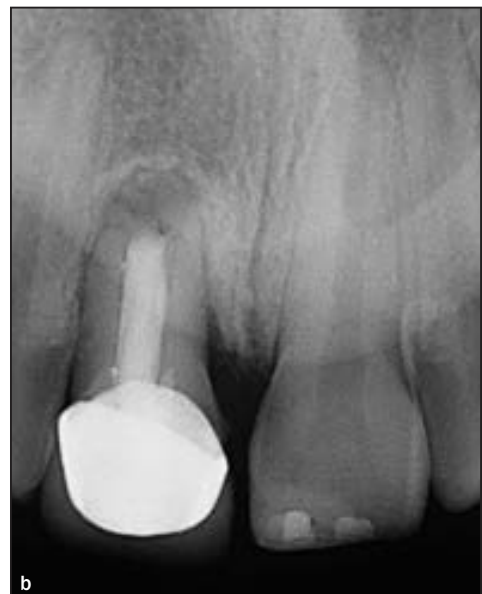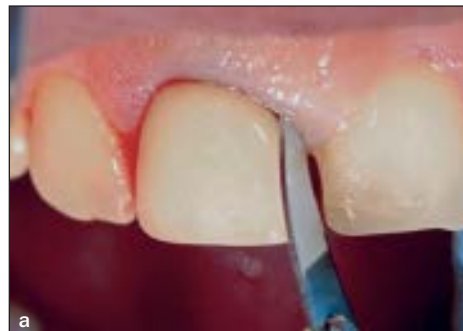### Data Collection

All measurements were performed by a single examiner who was not involved in the surgical therapy. Initial measurements were recorded on the day of surgery. Each patient received a standardized baseline examination consisting of dental and periodontal evaluation of the area around the involved tooth. Periapical radiographs were obtained using the long-cone paralleling technique with the aid of regular film holders (RVG 6000, Carestream Dental) to estimate the preoperative vertical ridge dimension. Each radiographic image was calibrated to compensate for potential differences attributed to radiographic distortion. Calibration was

**Fig 1** The longer orange line represents the line that connects the CEJ of the two neighboring teeth and was used as a reference point. The green line extended 5 mm apical to the reference line during all measurements. The shorter orange line represents the additional measurement that was taken from the CEJ of the neighboring tooth to ascertain reproducibility of the measurements in the mesiodistal plane.



**Figs 2a and 2b** A 37-year-old woman presented with a maxillary central incisor that was scheduled for extraction because of apical root resorption. A no. 12 blade was used to detach the supracrestal fibers and minimize distortion of the gingival architecture during extraction.



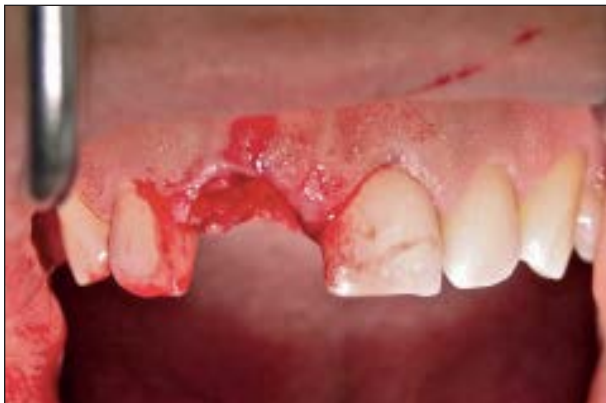performed by obtaining apicocoronal measurements of the length of teeth adjacent to the grafted site to the nearest tenth of a millimeter and adjusting the magnitude of the socket/site changes accordingly with the aid of specialized software (Dental Imaging Software version 6.1.7, Carestream Dental).<sup>25</sup> All measurements were performed twice at two separate time intervals by the same examiner, and the mean of the two measurements was reported.

Horizontal ridge dimensions were determined with the aid of an implant dentistry–specific caliper (bone caliper, G. Hartzell & Son) designed to penetrate soft tissue and assess bone width. The cemento-enamel junction (CEJ) of the teeth adjacent to the sites to be augmented was used as a fixed reference point. The caliper was placed at 5 mm below the line that connected the CEJs of the two neighboring teeth. Additionally,

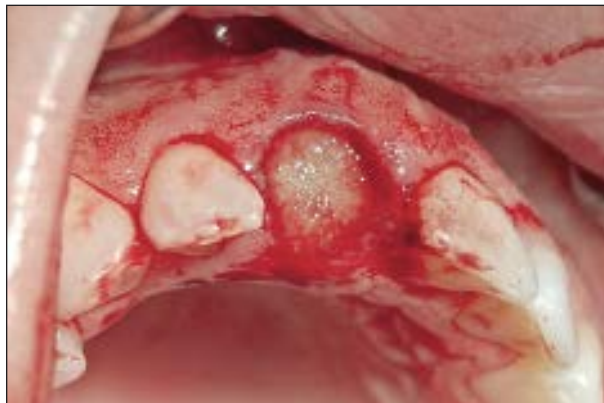the exact mesiodistal distance between the site of measurement and the root surface of the nearest tooth was recorded to ensure that the follow-up measurement would be standardized and reproducible<sup>26</sup> (Fig 1). For study sites adjacent to an edentulous area, such as a second molar, a line that was parallel to the alveolar crest and was coming through the neighboring tooth's CEJ was considered the reference point.

### Socket Preservation

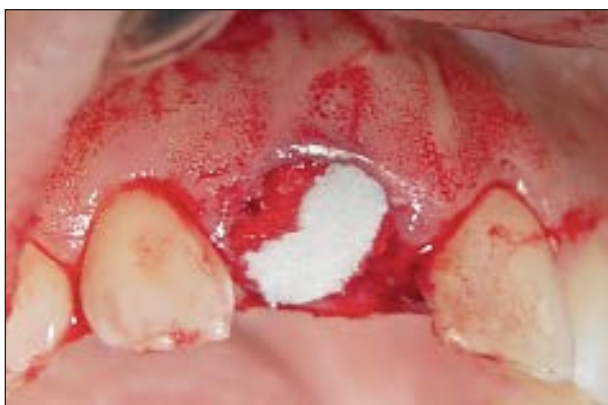All patients received dental prophylaxis and oral hygiene instructions approximately 15 days prior to the surgery and were allocated to either one of the test groups or the control group according to a randomization list. Each patient was given 1 g amoxicillin orally 1 hour before surgery. All surgical procedures were performed by the same operator (GK). The socket-plug



**Fig 3** Atraumatic handling of the socket during extraction allowed for preservation of the soft tissue architecture of the area.

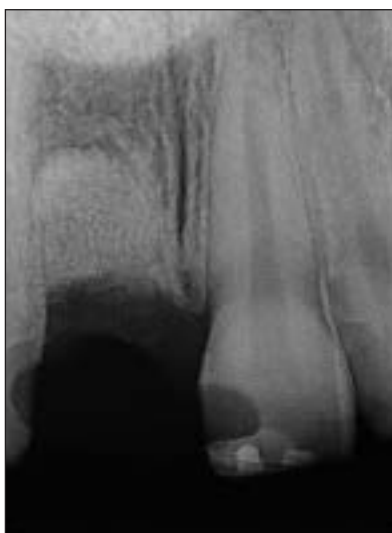

**Fig 4** Socket filled with putty bone substitute. The handling characteristics of putty materials allow for the filling of the socket in a single step, in contrast to particulate bone substitutes.



**Fig 5** The collagen plug is placed over the graft and becomes moldable when it comes into contact with blood.

**Fig 6 (Right)** Periapical radiograph showing the even fill of the socket thanks to the flow of the putty.



technique used in this study was previously described by Kotsakis et al.<sup>27</sup> The procedure consisted of cutting through the epithelial attachment with a 15c or 12b blade to transect the supracrestal fibers, severing the periodontal ligament fibers with a sharp periosteal, and completion of atraumatic tooth extraction as previously described (Figs 2a and 2b).

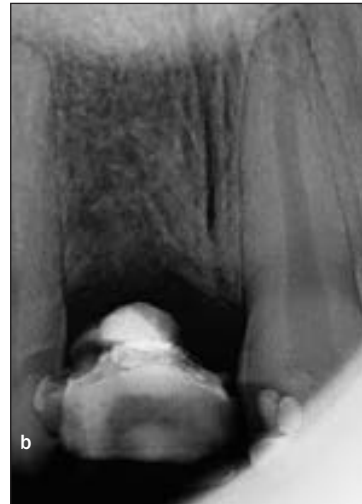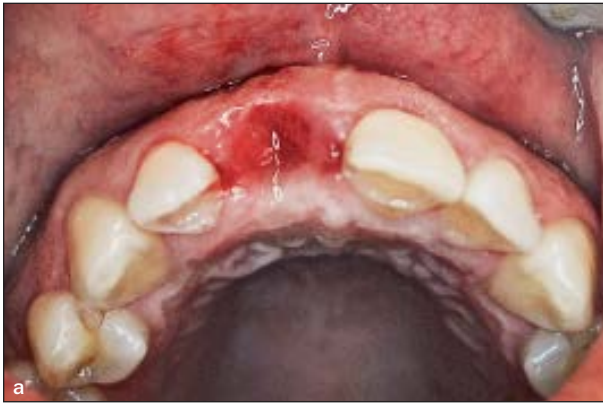All molar teeth were sectioned to ensure the least traumatic extraction possible. Following this, the alveolus was thoroughly degranulated, and care was given to avoid bidigital compression of the postextraction sockets, as this might lead to excessive bone loss<sup>27</sup> (Fig 3).

The BOV group received ABBM mixed with saline according to the manufacturer's instructions. This was gently condensed into the alveolar socket with a Goldman-Fox elevator up to the level of the bone crest. CPS was delivered to the PUT group through a cartridge syringe into the alveolar socket to the level of the bone crest (Fig 4). In both groups the socket was occluded using the lowest one-fourth of a collagen plug

(Collaplug, Zimmer Dental) and secured with a horizontal mattress suture using a 4-0 resorbable suture material (Vicryl, ETHICON) (Fig 5). The control group received no grafting or suturing following degranulation of the socket. A postoperative periapical radiograph was taken to verify the socket fill in the test groups (Fig 6).

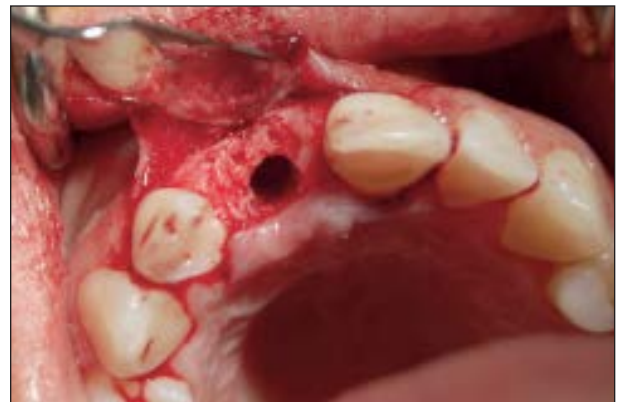No removable appliances were used, and the sockets were left to heal undisturbed. The edentulous sites were either provisionally restored with a resin-fiber-reinforced partial denture fixed on the neighboring teeth or left unrestored according to the patients' esthetic demands.

Postsurgical instructions included antibiotics (amoxicillin 500 mg three times daily for 7 days), chlorhexidine 0.2% oral gel for topical application (Chlorexil gel, Intermed), and nonsteroidal anti-inflammatory drugs (ibuprofen 400 mg four times daily for 3 days). Patients were also instructed to refrain from brushing or any mechanical trauma in the area for 2 weeks. Postoperative evaluations were done at 1, 3, and 6 weeks to check for



**Figs 7a and 7b** Clinical view of the healed ridge at 5 months postextraction. Adequate bone width preservation is evident. Radiographically, the trabecularization of the healed socket can be seen to resemble that of the neighboring pristine bone.

**Fig 8** Implant placement was performed by the same surgeon following a standardized protocol to minimize errors in MIT measurements. Note the good preservation of the buccal plate after 5 months of healing.



complications, including infection, wound dehiscence, and resorption. Clinical and radiographic postoperative measurements were recorded at approximately 5 months by the same blinded examiner who had performed the baseline measurements and was not involved in the surgical treatment (Figs 7a and 7b).

### Implant Placement Surgery

All patients who decided to proceed with implant placement for the rehabilitation of their edentulous area were scheduled for implant surgery at 5 months postextraction. Augmented sites were reentered via a crestal incision that was connected with sulcular incisions on the neighboring teeth. A full-thickness mucoperiosteal flap was raised, and preparation of the implant bed was executed according to the surgical protocol proposed by the implant manufacturer (Fig 8).

Surgical protocol was strictly adhered to by the surgeon to minimize any effect on maximum insertion

torque (MIT). The appropriate size of each implant was selected so that the implant extended no more than 3 mm beyond the apex of the socket, if clinically feasible, in an attempt to minimize the influence of the native bone on the MIT value. Each implant was inserted manually using an adjustable torque wrench. The torque wrench was calibrated to enable evaluation of the implant's primary stability. It was initially set to 10 N/cm<sup>2</sup> and was gradually increased in 5-N/cm<sup>2</sup> increments until the implant was fully seated in the desired position. MIT, if not absolute, was calculated to be in a range between the previous baseline point and the next determined torque value. For example, if the wrench "clicked" at 25 N/cm<sup>2</sup> but the implant was fully seated before the wrench clicked at 30 N/cm<sup>2</sup>, the implant was considered to have an MIT score of 20 to 29 N/cm<sup>2</sup>, since 20 N/cm<sup>2</sup> was the previous reference point. Implants were left to heal for 3 months and were then restored with cement-retained single crowns. All implants were followed for a minimum of 12 months postloading.

**Table 1 Demographic Data, Group Allocation, and Site Distribution of Patients in the Study**

	Study group		
	PUT	BOV	Control
No. of teeth	12	12	6
Mean age (y) (range)	43.3 (21–68)	39.8 (29–52)	43.8 (27–62)
Patient gender (M/F)	6/4	6/2	5/1
<b>Tooth type</b>			
Maxillary incisors	1	1	0
Maxillary premolars	4	4	0
Maxillary molars	1	3	0
Mandibular premolars	1	2	3
Mandibular molars	5	2	3

The obtained MIT was used as an index of primary implant stability to evaluate the bone quality at the healed sites. A classification system for MIT measurements in association with bone quality has not been published before. However, such an MIT measurement can be of clinical value, both as a prognostic index for the successful osseointegration of the implant and for the determination of the appropriate loading timing.<sup>28,29</sup>

The authors proposed an MIT index stratified into four gradients and associated it with bone density according to published data and the authors' clinical experience, as well as findings from this study for use in the analysis of the current findings. For the proposed MIT index, grade 1 = 10 to 19 N/cm<sup>2</sup>, ie, insufficient bone density; grade 2 = 20 to 29 N/cm<sup>2</sup>, ie, fair bone density; grade 3 = 30 to 34 N/cm<sup>2</sup>, ie, good bone density; and grade 4 = 35 N/cm<sup>2</sup> or above, ie, optimal bone density.

### Statistical Analysis

A power analysis was performed based on data from a recent controlled clinical study that used the same bone substitute as in the BOV group.<sup>5</sup> Normal distribution of the data was assumed for the power analysis. Based on the power analysis, a sample size of 12 sites per test group would have an 83% power of detecting 1 mm of difference in bone width resorption between the two groups. For the aforementioned sample size of 12 sites in each test group, power analysis revealed that a control group with 6 sites would have a 99% power of detecting a statistically significant difference between the test and control groups based on the findings of Cardaropoli et al.<sup>5</sup>

Means and standard deviations of all measurements were reported. Differences between each test group and the control group, as well as between the BOV and PUT test groups, as recorded at baseline and at the 5-month examinations, were analyzed using the

Mann-Whitney test. The total sample size was 30 split into three different groups: BOV, PUT, and CTRL. The Mann-Whitney *U* test was preferred over the Student *t* test for intergroup comparison because of the small sample size. The same statistical test was also used to evaluate the ordinal values of primary implant stability, as expressed by the MIT index, of implants in the BOV and PUT groups. A *P* value < .05 was considered to be statistically significant. Statistical calculations were performed using SPSS software (release 20.0 for Windows, SPSS Inc).

## RESULTS

Twenty-six patients were initially screened for participation in this study. After the application of the exclusion criteria, one man and one woman were excluded from the study because of a diagnosis of lung cancer a few days after the screening appointment and a history of pemphigus vulgaris, respectively. The remaining 24 patients, requiring 30 extractions, completed the study. Each test group included 12 extraction sites, whereas the control group included 6 extraction sites. The tooth population consisted of 2 incisors, 14 premolars, and 14 molars; 14 teeth were located in the maxilla and 16 were in the mandible (Table 1).

### Dimensional Ridge Changes

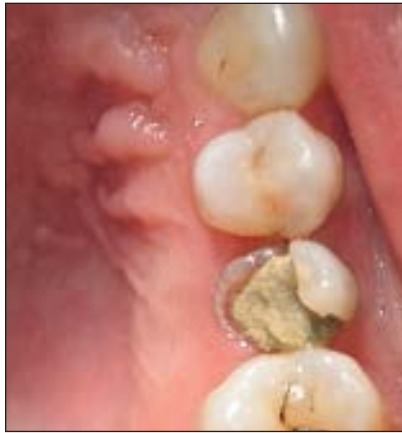Postgrafting radiographs revealed adequate bone fill in all sockets of both test groups. An average decrease of  $0.83 \pm 0.32$  mm and  $0.88 \pm 0.30$  mm in ridge height was noted for the PUT and BOV groups, respectively. The vertical change in both test groups was similar and less than that of the CTRL group, which presented a mean reduction of  $1.12 \pm 0.23$  mm, but this difference was not statistically significant.

At 5 months postgrafting, the mean reduction in the buccolingual dimension was  $1.26 \pm 0.41$  mm for the PUT group and  $1.39 \pm 0.57$  mm for the BOV group, while sockets in the CTRL group lost a mean of  $2.53 \pm 0.59$  mm (Fig 9). The mean difference in horizontal ridge width between each test group and the control group was statistically significant (*P* < .05) for both test groups. Changes in ridge width and height for all groups are presented in Table 2.

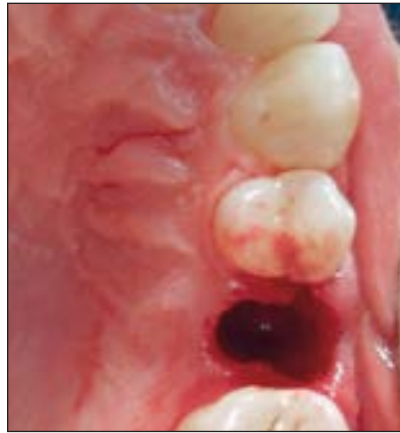### Primary Implant Stability Measurements

Following healing of the extraction sockets, nine PUT group participants, eight BOV group patients, and three CTRL participants decided to proceed with implant placement. Initially, patients from all study groups were planned to receive implants at 5 months postextraction. However, during the first implant surgery in the BOV group, it was decided that an additional month of

**Figs 9a to 9f** Clinical views of a hopeless maxillary second premolar showing significant preservation of alveolar ridge width following socket grafting with ABBM.



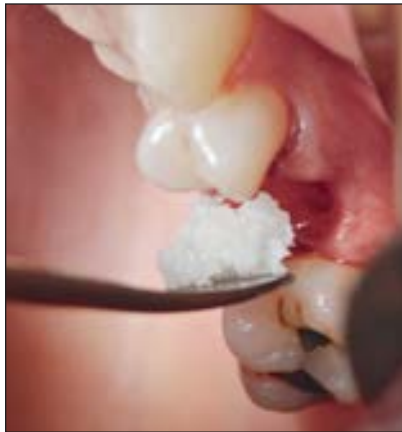**Fig 9a** A 43-year-old female nonsmoker presented for extraction of her maxillary left second premolar, which had been deemed nonrestorable following removal of tooth decay.



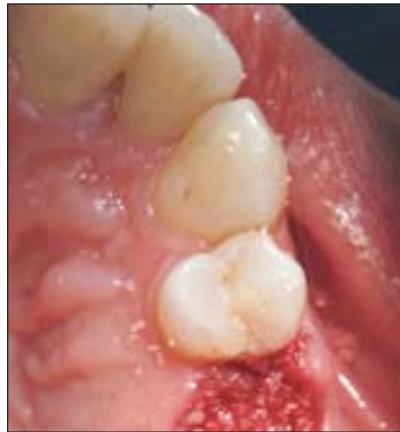**Fig 9b** Atraumatic extraction led to maintenance of the soft tissue architecture in the area and prevented fracture of the buccal plate.



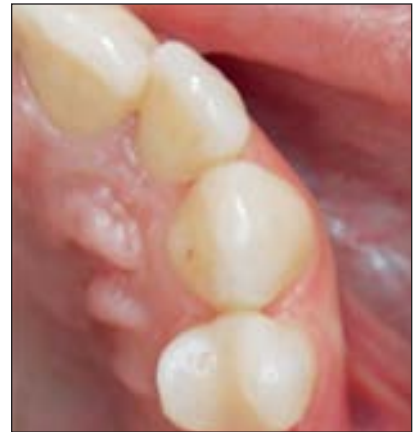**Fig 9c** ABBM was used to fill the extraction socket. When a particulate bone graft is used, it must be hydrated prior to application in the defect; in contrast, the putty is premixed and readily available for application intraorally.



**Fig 9d** The particulate ABBM was delivered in increments using a Goldman-Fox elevator.



**Fig 9e** Clinical image of the socket filled with ABBM to the level of the bone crest. Subsequently, a collagen plug was placed to contain the bone particles according to the "socket-plug" technique.



**Fig 9f** Clinical view of postoperative healing revealed very good maintenance of alveolar ridge width. In this clinical case, 0.5 mm of loss in the orofacial dimension was recorded at 5 months postextraction.

**Table 2** Intergroup Comparison of Ridge Dimensions at Baseline and at 5 Months

Time	Ridge width (mm)			Ridge height (mm)		
	PUT	BOV	Control	PUT	BOV	Control
Baseline	8.68 ± 1.08	9.5 ± 1.86	8.67 ± 0.51	10.58 ± 1.67	10.63 ± 2.06	9.67 ± 2.26
5 mo	7.42 ± 0.96	8.11 ± 1.53	6.13 ± 0.45	9.75 ± 1.77	9.74 ± 1.94	8.55 ± 2.20
Difference	-1.26	-1.39	-2.53	-0.84	-0.88	-1.12

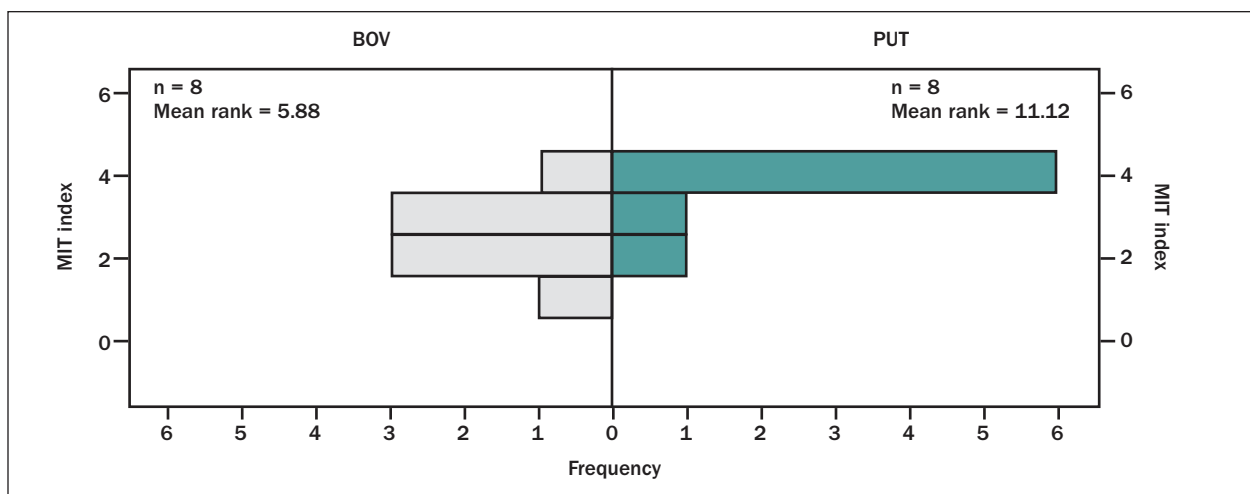
healing was essential prior to reentering the rest of the sockets restored with ABBM. The PUT group was reentered as planned at 5 months. Two of the three patients in the CTRL group required ridge augmentation prior to implant placement, while the third patient received an implant that achieved 35 N/cm<sup>2</sup> of MIT. Consequently,

the control group was excluded from primary implant stability analysis. All implants placed in the PUT group achieved grade 4 MIT, except for one case where the stability was grade 3 and another that was grade 2. The MIT grades for the eight BOV implants were one in grade 4, three in grade 3, three in grade 2, and one in grade 1.

**Table 3** Distribution of Implant Sites and Corresponding MIT Index Measurements

Site	Implant osseointegration	Primary stability	MIT Index		Primary stability	Implant osseointegration	Site
			PUT	BOV			
30	Y	Optimal	4	1	Insufficient	N	14
19	Y	Optimal	4	2	Fair	Y	2
12	Y	Fair	2	2	Fair	Y	12
13	Y	Good	3	2	Fair	Y	13
30	Y	Optimal	4	3	Good	Y	29
20	Y	Optimal	4	3	Good	Y	3
8*	Y	Optimal	4	4	Optimal	Y	13
18	Y	Optimal	4	3	Good	Y	30
4	Y	Optimal	4				

\*This site was removed from MIT comparison because it extended more than 3 mm into native bone at the time of implant placement.



**Fig 10** Primary implant stability grades for all implants included in the intergroup comparison from each of the test groups.

All implants extended less than 3 mm beyond the apex of the socket, except for one maxillary central incisor in the PUT group that had undergone apical root resorption. Because of the decreased root length preoperatively, the implant was placed to extend approximately 5 mm into native bone. To avoid bias in the results, the site was excluded from the intergroup comparison of primary implant stability. The difference between the two test groups was statistically significant in favor of the PUT group in terms of primary implant stability ( $P < .05$ ) (Table 3, Fig 10).

The overall implant success rate was 94.1% (16/17). No implants were lost in the PUT group, and one implant that had been placed at 5 months failed in the BOV group. All osseointegrated implants were loaded 3 months postimplantation.

At 12 to 20 months postloading, all patients reported satisfactory function of the implant-supported crowns, as depicted by lack of implant mobility and absence of pain upon percussion. Intraoral clinical

examination revealed healthy peri-implant mucosa without clinical signs of inflammation of the peri-implant tissues. All osseointegrated implants functioned well during the follow-up period, for a cumulative postloading success rate of 100%.

## DISCUSSION

This randomized, controlled, clinical study was designed to evaluate the dimensional stability of the alveolar ridge after the placement of either ABBM or CPS in fresh extraction sockets. Both test groups demonstrated similar clinical and radiographic outcomes that were statistically significantly more favorable in comparison to the control group in terms of alveolar ridge width preservation.

The present results are commensurate with those of Mardas et al, who assessed the effect of ABBM placed in fresh extraction sockets covered with a collagen



membrane and found an average 1.1-mm reduction in buccolingual ridge width 8 months after treatment.<sup>30</sup> When reviewing results from the present study, the variance between maxillary and mandibular sites among the test groups and the control group following random allocation should also be taken into consideration. Although the control group included only mandibular extraction sockets, the magnitude of ridge resorption seen in this group was consistent with results reported in a recent systematic review that examined postextraction dimensional alterations of both maxillary and mandibular sites.<sup>31</sup> Specifically, evidence from the literature shows that socket preservation therapies limit, but do not prevent, vertical and horizontal changes of the alveolar ridge, which may resorb up to 2.64 mm and 3.48 mm, respectively.<sup>31</sup>

The current study also assessed and classified the quality of bone in the regenerated sites based on clinical rather than histologic criteria. The majority of previously published clinical trials aimed to determine the bone quality of augmented sockets through histomorphometric measurements. No analyses were made regarding the clinical bone quality observed during implant site preparation and placement.<sup>32</sup> Bone biopsy specimens obtained after healing are the most appropriate method for assessing bone quality, but ethical considerations and/or lack of funding may frequently hinder their use.

In search of a means to clinically assess bone quality, many recent research reports have emphasized the positive correlation between bone quality and primary implant stability.<sup>22,23,33,34</sup> Current evidence suggests that primary implant stability significantly correlates with bone quality, and thus, there may be merit in the use of implant stability as a surrogate for the indirect assessment of bone quality. Primary implant stability has been shown to be associated with bone density, as it contributes to the initial interlocking between alveolar bone and the body of the implant.<sup>35</sup> The main determinants of primary implant stability are surgical technique, implant design, and bone quality.<sup>36</sup> A standardized drill sequence was used for all the implants placed in this clinical trial, and the same type of implant was placed; this minimized the influence of other factors that could interfere with primary stability so that bone quality would be the main variable. Although efforts were made to ensure that implants were placed no further than 3 mm beyond the apex of the socket to minimize any additive effect to the implant's primary stability, this limitation should be considered when reviewing results from these measurements.

Several methods have been used previously to estimate primary implant stability, including resonance frequency analysis, Periotest, removal torque, and MIT. Many authors have proposed the use of MIT as a

reliable index for primary implant stability and have found it to be equivalent or superior to implant stability quotient (ie, resonance frequency analysis).<sup>37–40</sup> Moreover, Esposito et al, in a systematic review on the timing of loading of dental implants, concluded that a high degree of primary implant stability, as expressed by a high IT, is one of the prerequisites for successful immediate and early loading.<sup>28</sup> MIT was chosen as the evaluation parameter in the present study because of its reliability and ease of clinical use. The need to quantify the findings of this study and assist future researchers led the current authors to introduce the MIT index. The rationale for clinical assessment of bone quality was to determine whether the delayed resorption of the graft material has a clinical impact on the placement of implants 5 to 6 months postoperatively.<sup>41</sup>

Lower MIT grade and associated primary implant stability were observed in sockets treated with ABBM in the present study population. In comparison, sockets in the PUT group exhibited higher MIT index recordings, associated with denser tissue, as evaluated clinically in the healed sites. Similar results were published by Felice et al, who stated that it seemed difficult to achieve adequate primary stability for implants placed in sockets preserved with ABBM after only 4 months of healing.<sup>42</sup>

A limitation of the present study includes the location of the healed sites where implants were placed. The BOV group included three posterior maxillary sites of eight investigated sites, while the PUT group did not include any sites in the posterior maxilla. Also, although the implant body was mainly surrounded by regenerated tissue and not by native bone, this limitation should be considered when evaluating results based on the MIT index.

To aid in the interpretation of results from the assessment of MIT as a measure of primary implant stability, the authors developed the MIT index classification based on the current data and rationale from preceding publications. Magno Filho et al reported a correlation between the MIT of implants placed in the mandible and maxilla of different bone densities.<sup>39</sup> Bone densities were classified according to Lekholm and Zarb,<sup>43</sup> and type I and II bone densities were grouped and found to be associated with MIT measurements above 35 N/cm<sup>2</sup>. A similar study by Barewal et al related type III and IV bone densities according to Lekholm and Zarb<sup>43</sup> to MIT values of 17 and 10 N/cm<sup>2</sup> or less, respectively.<sup>44</sup> Based on the data from the literature and the results of this study, the authors suggest that grade 4 of the MIT index represents the optimal insertion torque and may be associated with type I and II bone.<sup>39,43,44</sup> Immediate loading of implants may be indicated when grade 4 MIT is achieved<sup>24,28</sup> (Table 4). Grade 3 indicates type II bone density, or a layer of cortical bone that surrounds trabecular bone (type III).<sup>39,43,45</sup> Immediate

**Table 4 Clinical Guidelines for Implant Loading Based on the Grades of the MIT Index**

MIT Index	MIT	Bone density	Suggested loading protocol
Grade 1	10–19 N/cm <sup>2</sup>	Insufficient	Delayed (4–6 months of healing)
Grade 2	20–29 N/cm <sup>2</sup>	Fair	Conventional
Grade 3	30–34 N/cm <sup>2</sup>	Good	Conventional or early
Grade 4	> 35 N/cm <sup>2</sup>	Optimal	Immediate or early

Grade 1 MIT index is correlated with insufficient bone density. In this case, an increased healing time is recommended for successful osseointegration. When grade 2 MIT is achieved, conventional loading is justifiable. When grade 3 MIT is recorded, evidence from the literature shows adequate implant success rates for conventional or early loading. In cases where increased primary stability is reached (grade 4 MIT), immediate loading can be advocated with appropriate case selection.<sup>28,36,40</sup>

or early loading may be performed, depending on the clinician's experience.<sup>24,28,44</sup> Grade 2 MIT may indicate type IV bone, where only a thin cortical layer can contribute to primary stability.<sup>39,43,45</sup> In this clinical situation conventional loading is indicated. Finally, grade 1 MIT can be associated with type IV bone without even a dense layer of cortical bone, where the alveolar ridge consists entirely of loose trabecular bone.<sup>39,43</sup> In cases of previous socket preservation, the ridge may be made up of remaining particles of the bone substitute that are still undergoing resorption and substitution by newly formed tissue.<sup>7,18</sup> The reason for this may be either that the specific type of bone substitute needed a more extended healing period to remodel to its low substitution rate, or that overcondensation of particulate graft material occurred during packing of the biomaterial in the socket. Overcondensation of the graft may increase the diffusion distance for oxygen and nutrients to reach the area, resulting in significant delay of graft substitution, or even graft failure.<sup>46</sup> In cases of grade 1 MIT, it is advisable to delay loading by approximately 4 to 8 weeks.<sup>28,47</sup> For sites with MIT less than 10 N/cm<sup>2</sup>, the authors suggest delaying implant placement until a later time, or, if possible, placement of a larger-diameter implant so that at least 10 N/cm<sup>2</sup> of primary stability can be achieved (Table 4).

The aim of contemporary socket preservation techniques should be the conversion of bone substitutes into human bone with a load-bearing capacity in a timely manner. The results of this study suggest that the dimensional stability of the ridge was preserved adequately in both test groups, but the ABBM-grafted sites required an extended healing time for placement of an implant with adequate primary stability. Therefore, it could be stated that, within the limitations of this study, CPS putty is indicated when quicker reentry for implant placement is desired, while ABBM may be suggested for transitional socket preservation.

Large-scale randomized controlled clinical trials that will attempt to correlate clinical and histologic outcomes of socket preservation with ABBM and CPS putty are required to verify the present findings.

## CONCLUSION

Based on these clinical findings, both tested bone substitutes can be recommended for preservation of the width of the alveolar ridge following the extraction of a tooth. The use of calcium phosphosilicate putty might be more suitable for achieving better primary stability for implants placed at 5 to 6 months postextraction, since its faster healing may provide a clinical advantage during implant placement.

## ACKNOWLEDGMENTS

This project was supported by grant number 1UL1RR033183 from the National Center for Research Resources and grant number 8UL1TR000114-02 from the National Center for Advancing Translational Sciences of the National Institutes of Health to the University of Minnesota Clinical and Translational Science Institute. The authors wish to thank Novabone Products LLC, Alachua, Florida, for providing partial support for the test materials that were used in this study.

The authors declare that they have no conflicts of interest.

## REFERENCES

- Atwood DA. Reduction of residual ridges: A major oral disease entity. *J Prosthet Dent* 1971;26(3):266–279.
- Tallgren A. The continuing reduction of the residual alveolar ridges in complete denture wearers: A mixed-longitudinal study covering 25 years. *J Prosthet Dent* 1972;27(2):120–132.
- Allegrini S Jr, Koenig B Jr, Allegrini MR, et al. Alveolar ridge sockets preservation with bone grafting—Review. *Ann Acad Med Stetin* 2008;54(1):70–81.
- Barone A, Ricci M, Tonelli P, Santini S, Covani U. Tissue changes of extraction sockets in humans: A comparison of spontaneous healing vs. ridge preservation with secondary soft tissue healing. *Clin Oral Implants Res* 2012. [Epub ahead of print]
- Cardaropoli D, Tamagnone L, Roffredo A, Gaveglione L, Cardaropoli G. Socket preservation using bovine bone mineral and collagen membrane: A randomized controlled clinical trial with histologic analysis. *Int J Periodontics Restorative Dent* 2012;32(4):421–430.
- Maresh L, Kotsakis G, Venkataraman N, Shukla S, Prasad H. Ridge preservation with the socket-plug technique utilizing an alloplastic putty bone substitute or a particulate xenograft: a histological pilot study. *J Oral Implantol* 2013 Jun 17. [Epub ahead of print]

7. Tolstunov L, Chi J. Alveolar ridge augmentation: Comparison of two socket graft materials in implant cases. *Compend Contin Educ Dent* 2011;32(9):E146–155.
8. Mahesh L, Salama MA, Kurtzman GM, Joachim FP. Socket grafting with calcium phosphosilicate alloplast putty: A histomorphometric evaluation. *Compend Contin Educ Dent* 2012;33(8):e109–115.
9. Cho YR, Gosain AK. Biomaterials in craniofacial reconstruction. *Clin Plast Surg* 2004;31(3):377–385.
10. Ghoreishian SM, Jamalpoor M. Clinical, radiographic, and histologic comparison of ridge augmentation with bioactive glass alone and in combination with autogenous bone graft. *Dent Res J* 2005;2(2):1–9.
11. Hench LL. The story of bioglass. *J Mater Sci Mater Med* 2006;17(11):967–978.
12. Hu YC, Zhong JP. Osteostimulation of bioglass. *Chin Med J (Engl)* 2009;122(19):2386–2388.
13. Kotsakis G, Chrepa V, Katta, S. Practical application of the newly introduced natural bone regeneration (NBR) concept utilizing alloplastic putty. *Int J Oral Implantol Clin Res* 2011;2(3):145–149.
14. Vance GS, Greenwell H, Miller RL, et al. Comparison of an allograft in an experimental putty carrier and a bovine-derived xenograft used in ridge preservation: A clinical and histologic study in humans. *Int J Oral Maxillofac Implants* 2004;19(4):491–497.
15. Block MS, Ducote CW, Mercante DE. Horizontal augmentation of thin maxillary ridge with bovine particulate xenograft is stable during 500 days of follow-up: Preliminary results of 12 consecutive patients. *J Oral Maxillofac Surg* 2012;70(6):1321–1330.
16. Patel K, Mardas N, Donos N. Radiographic and clinical outcomes of implants placed in ridge preserved sites: A 12-month post-loading follow-up. *Clin Oral Implants Res* 2013;24(6):599–605.
17. Piattelli M, Favero GA, Scarano A, Orsini G, Piattelli A. Bone reactions to anorganic bovine bone (Bio-Oss) used in sinus augmentation procedures: A histologic long-term report of 20 cases in humans. *Int J Oral Maxillofac Implants* 1999;14(6):835–840.
18. Artzi Z, Tal H, Dayan D. Porous bovine bone mineral in healing of human extraction sockets: 2. Histochemical observations at 9 months. *J Periodontol* 2001;72(2):152–159.
19. Carmagnola D, Berglundh T, Araujo M, Albrektsson T, Lindhe J. Bone healing around implants placed in a jaw defect augmented with Bio-Oss. An experimental study in dogs. *J Clin Periodontol* 2000;27(11):799–805.
20. Orsini G, Traini T, Scarano A, et al. Maxillary sinus augmentation with Bio-Oss particles: A light, scanning, and transmission electron microscopy study in man. *J Biomed Mater Res B Appl Biomater* 2005;74(1):448–457.
21. Berglundh T, Lindhe J. Healing around implants placed in bone defects treated with Bio-Oss. An experimental study in the dog. *Clin Oral Implants Res* 1997;8(2):117–124.
22. Chai J, Chau AC, Chu FC, Chow TW. Correlation between dental implant insertion torque and mandibular alveolar bone density in osteopenic and osteoporotic subjects. *Int J Oral Maxillofac Implants* 2012;27(4):888–893.
23. Oh JS, Kim SG. Clinical study of the relationship between implant stability measurements using Periotest and Osstell mentor and bone quality assessment. *Oral Surg Oral Med Oral Pathol Oral Radiol* 2012;113(3):e35–40.
24. Strub JR, Jurdzik BA, Tuna T. Prognosis of immediately loaded implants and their restorations: A systematic literature review. *J Oral Rehabil* 2012;39(9):704–717.
25. Grandi T, Garuti G, Guazzi P, Tarabini L, Forabosco A. Survival and success rates of immediately and early loaded implants: 12-month results from a multicentric randomized clinical study. *J Oral Implantol* 2012;38(3):239–249.
26. Corinaldesi G, Pieri F, Sapigni L, Marchetti C. Evaluation of survival and success rates of dental implants placed at the time of or after alveolar ridge augmentation with an autogenous mandibular bone graft and titanium mesh: a 3- to 8-year retrospective study. *Int J Oral Maxillofac Implants* 2009;24(6):1119–1128.
27. Kotsakis G, Chrepa V, Marcou N, Prasad H, Hinrichs J. Flapless alveolar ridge preservation utilizing the “socket-plug” technique: Clinical technique and review of the literature. *J Oral Implantol* 2012 Nov 12. [Epub ahead of print]
28. Esposito M, Grusovin MG, Achille H, Coulthard P, Worthington HV. Interventions for replacing missing teeth: Different times for loading dental implants. *Cochrane Database Syst Rev* 2009(1):CD003878.
29. Orsini E, Giavaresi G, Trire A, Ottani V, Salgarello S. Dental implant thread pitch and its influence on the osseointegration process: An in vivo comparison study. *Int J Oral Maxillofac Implants* 2012;27(2):383–392.
30. Mardas N, Chadha V, Donos N. Alveolar ridge preservation with guided bone regeneration and a synthetic bone substitute or a bovine-derived xenograft: A randomized, controlled clinical trial. *Clin Oral Implants Res* 2010;21(7):688–698.
31. Ten Heggeler JM, Slot DE, Van der Weijden GA. Effect of socket preservation therapies following tooth extraction in non-molar regions in humans: A systematic review. *Clin Oral Implants Res* 2011;22(8):779–788.
32. Misch C, Wang HL. Clinical applications of recombinant human bone morphogenetic protein-2 for bone augmentation before dental implant placement. *Clin Adv Periodontics* 2011;1(2):118–131.
33. Lee S, Gantes B, Riggs M, Crigger M. Bone density assessments of dental implant sites: 3. Bone quality evaluation during osteotomy and implant placement. *Int J Oral Maxillofac Implants* 2007;22(2):208–212.
34. Ribeiro-Rotta RF, de Oliveira RC, Dias DR, Lindh C, Leles CR. Bone tissue microarchitectural characteristics at dental implant sites part 2: Correlation with bone classification and primary stability. *Clin Oral Implants Res* 2012 Oct 29. [Epub ahead of print]
35. Berglundh T, Abrahamsson I, Lang NP, Lindhe J. De novo alveolar bone formation adjacent to endosseous implants. *Clin Oral Implants Res* 2003;14(3):251–262.
36. Sennerby L, Meredith N. Implant stability measurements using resonance frequency analysis: Biological and biomechanical aspects and clinical implications. *Periodontol* 2000 2008;47:51–66.
37. Tabassum A, Meijer GJ, Wolke JG, Jansen JA. Influence of the surgical technique and surface roughness on the primary stability of an implant in artificial bone with a density equivalent to maxillary bone: A laboratory study. *Clin Oral Implants Res* 2009;20(4):327–332.
38. Ahn SJ, Leesungbok R, Lee SW, Heo YK, Kang KL. Differences in implant stability associated with various methods of preparation of the implant bed: An in vitro study. *J Prosthet Dent* 2012;107(6):366–372.
39. Magno Filho LC, Cirano FR, Hayashi F, et al. Assessment of the correlation between insertion torque and resonance frequency analysis of implants placed in bone tissue of different densities. *J Oral Implantol* 2012 Apr 16. [Epub ahead of print]
40. Schincaglia GP, Marzola R, Scapoli C, Scotti R. Immediate loading of dental implants supporting fixed partial dentures in the posterior mandible: A randomized controlled split-mouth study—machined versus titanium oxide implant surface. *Int J Oral Maxillofac Implants* 2007;22(1):35–46.
41. Vignoletti F, Matesanz P, Rodrigo D, et al. Surgical protocols for ridge preservation after tooth extraction. A systematic review. *Clin Oral Implants Res* 2012;23(suppl 5):22–38.
42. Felice P, Soardi E, Piattelli M, et al. Immediate non-occlusal loading of immediate post-extractive versus delayed placement of single implants in preserved sockets of the anterior maxilla: 4-month post-loading results from a pragmatic multicentre randomised controlled trial. *Eur J Oral Implantol* 2011;4(4):329–344.
43. Lekholm U, Zarb G. Patient selection and preparation. In: Brånemark PI, Zarb GA, Albrektsson T (eds). *Tissue-Integrated Prostheses: Osseointegration in Clinical Dentistry*. Chicago: Quintessence, 1985:199–209.
44. Barewal RM, Stanford C, Weesner TC. A randomized controlled clinical trial comparing the effects of three loading protocols on dental implant stability. *Int J Oral Maxillofac Implants* 2012;27(4):945–956.
45. Salimov F, Tatli U, Kurkcu M, et al. Evaluation of relationship between preoperative bone density values derived from cone beam computed tomography and implant stability parameters: A clinical study. *Clin Oral Implants Res* 2013 Jun 17. [Epub ahead of print]
46. Soltan M, Smiler DG, Soltan C, Prasad HS, Rohrer MD. Theoretical model for bone graft success. *Implant Dent* 2012;21(4):295–301.
47. Trisi P, Todisco M, Consolo U, Travaglini D. High versus low implant insertion torque: A histologic, histomorphometric, and biomechanical study in the sheep mandible. *Int J Oral Maxillofac Implants* 2011;26(4):837–849.